

## Unstable Less Common Chance Fracture

Ali RIAZI,<sup>1</sup> Samad Shams VAHDATI,<sup>2</sup> Arezou TAJLIL<sup>3</sup>

Departments of <sup>1</sup>Neurosurgery, <sup>2</sup>Emergency, Tabriz University of Medical Science; <sup>3</sup>Tabriz University of Medical Science, Tabriz, Iran

A 25-year-old boy presented to the emergency room with multiple trauma after a car crash in which the car had collided with a guardrail. The patient had been in the front passenger seat, wearing a seatbelt. At presentation, he was awake and complaining only of back pain. On examination, his vital signs were stable. He had tenderness over the vertebrae and a contusion where the seatbelt had been positioned over his trunk. His lungs were clear to auscultation bilaterally, and he had no respiratory distress. His heart sounds were normal, without a murmur or gallop. He had no tenderness over the sternum. His abdomen was soft to the touch with no abnormal findings. Cranial nerves were intact. Muscle strength was 5/5 for all limbs. Deep tendon reflexes (DTRs) were 2+. The patient did not have any motor or sensory deficits on neurological exam.

Due to his crash injury, focused assessment with sonography in trauma (FAST) was performed in the emergency room, and there were no abnormal findings. A brain computed tomography (CT) scan was performed, and the results were normal. Lateral neck radiography showed no abnormal findings.

Due to his pain, the tenderness over the vertebrae, and the contusion over his trunk, a vertebral plain radiograph was obtained (Figure 1). Based on the plain radiography findings, a vertebral CT scan was performed (Figure 2).

[see page 32 for diagnosis]

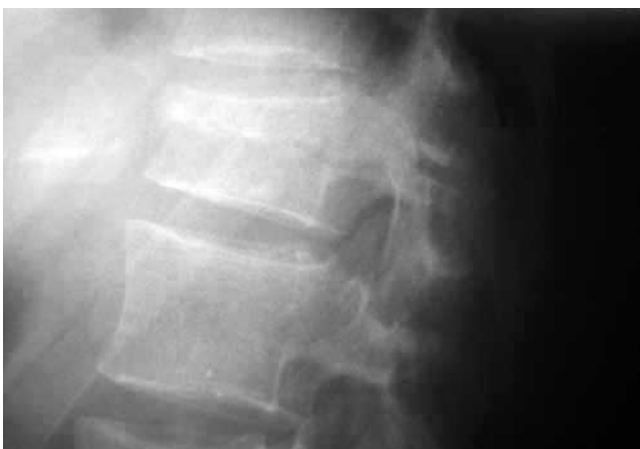

Figure 1.

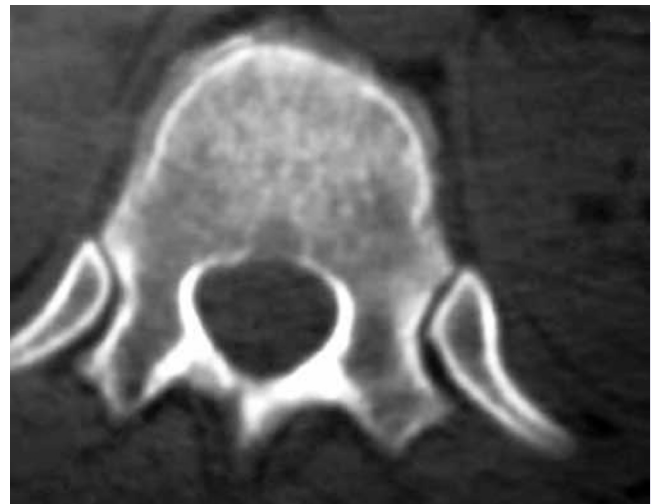

Figure 2.

Submitted: 07.07.2012 Accepted: 17.02.2013 Published online: 18.07.2013

Correspondence: Dr. Samad Shams Vahdati. No 1, Gholestan 2, Pezeshkan Alley, Abrasani Street Tabriz, Iran.

e-mail: sshamsv@yahoo.com



Open access under [CC BY-NC-ND license](#).

[see page 1]

## DIAGNOSIS: Chance Fracture

A chance fracture, a type of fracture caused by a flexion distraction mechanism,<sup>[1]</sup> was identified. Missing chance fractures in a multiple trauma patient can cause future complications, such as kyphosis or pain.<sup>[2]</sup> Chance fractures are typically caused by seatbelts during car crashes.<sup>[1]</sup> If a fracture has been caused by a seatbelt, a contusion over the trunk may be present which can alert the physician to the possibility of a chance fracture.<sup>[3]</sup>

Chance fractures extend horizontally from the tip of the transverse process on one side through the pedicles and laminae to the tip of the opposite transverse process. The fracture may involve the posterior part of the vertebral body. However, involvement of the anterior part of the vertebral body is not common, and chance fractures with anterior involvement are usually not very severe.<sup>[4]</sup> In cases of fractures with flexion-distraction mechanisms, patients should be examined for intraabdominal injuries.<sup>[1,3,4]</sup>

Chance-type fractures are unstable injuries that present without neurological deficit and may have subtle radiographic signs.<sup>[1]</sup> CT can help in diagnosing vertebral column damage and identifying patients with risk of acute neurologic compromise.<sup>[1]</sup> The most commonly used treatment for chance fracture is closed management; however, open surgery has also been reported.<sup>[5]</sup>

In our case, we observed failure of the posterior and

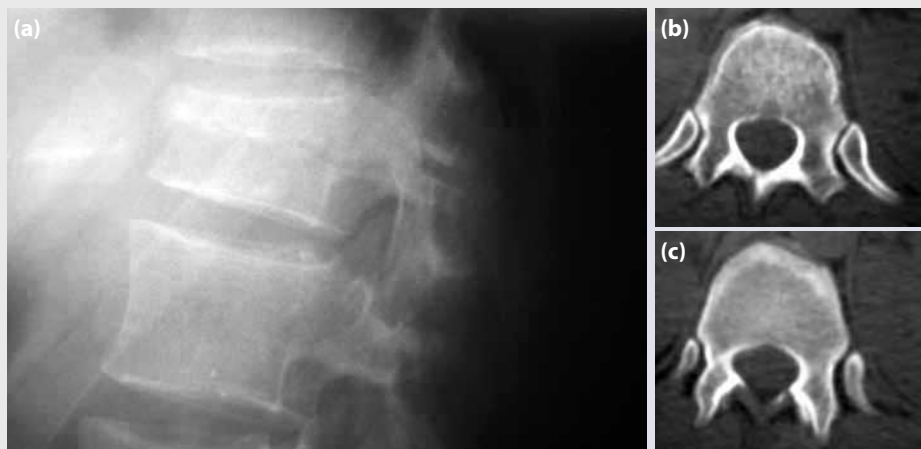
middle vertebra with anterior wedging. Due to the severe fracture, instability, and the probability of neurological consequences, operative management and internal fixation were performed without any complications.

### Conclusion

Severity and the probability of neurological consequences are the factors which determine the importance of considering surgical management for a diagnosed chance fracture.

### References

1. Bernstein MP, Mirvis SE, Shanmuganathan K. Chance-type fractures of the thoracolumbar spine: imaging analysis in 53 patients. *AJR Am J Roentgenol* 2006;187:859-68.
2. Schoenfeld AJ, Wood KB, Fisher CF, Fehlings M, Oner FC, Bouchard K, et al. Posttraumatic kyphosis: current state of diagnosis and treatment: results of a multinational survey of spine trauma surgeons. *J Spinal Disord Tech* 2010;23:1-8.
3. Banerjee A. Seat belts and injury patterns: evolution and present perspectives. *Postgrad Med J* 1989;65:199-204.
4. Greenbaum E, Harris L, Halloran WX. Flexion fracture of the lumbar spine due to lap-type seat belts. *Calif Med* 1970;113:74-6.
5. Yi L, Jingping B, Gele J, Baolier X, Taixiang W. Operative versus non-operative treatment for thoracolumbar burst fractures without neurological deficit. *Cochrane Database Syst Rev* 2006;4:CD005079.



**Figure 1.** (a) A thoracic wedge fracture of the T12 vertebra. (b, c) CT images of the fracture in three columns.