



Access this article online

Quick Response Code:



Website:

www.turkjemergmed.org

DOI:

10.4103/2452-2473.329628

Case Report

Complicated spontaneous intercostal lung hernia - A rare clinical case

Ivan Petkov Novakov^{1*}, Velizar Dafinov Hadzhiminev¹, Pavel Todorov Timonov²

Departments of ¹Special Surgery and ²Forensic Medicine, Medical Faculty, Medical University, Plovdiv, Bulgaria

Abstract:

Spontaneous lung herniation is a rare pathological entity. We present a case of intercostal type of spontaneous lung hernia after heavy lifting complicated with huge soft tissue hematoma, single rib fracture, hemothorax, diaphragmatic laceration, and great omentum pleural cavity herniation in a 46-year-old man. His comorbidities were arterial hypertension, congestive heart failure, and type II diabetes mellitus and had no history of trauma, surgical procedures in his thoracic wall, or chronic obstructive pulmonary disease. Physical examination revealed a huge left-sided flank hematoma. Chest X-ray determined stable intercostal lung hernia confirmed by chest computed tomography. Conventional approach by left mid-lateral thoracotomy was used for surgical repair of the lung hernia and stabilization of the intercostal space. The patient was discharged on the 9th postoperative day in a good condition. Control examination 2 years after the operation found no deformation of the thorax or recurrence of the lung hernia. This is a case of interest of spontaneous intercostal lung hernia because of the number and type of associated injuries. This case demonstrates low morbidity and good postoperative result by conventional surgery in intercostal lung hernias.

Keywords:

Hernia, lung, thoracotomy

Introduction

Lung herniation is defined as a protrusion of the lung beyond the normal confines of the thoracic cavity. This is a rare pathological entity with fewer than 300 reported cases in the literature presented mainly as "a single case" reports.^[1,2] According to their location, lung hernias can be cervical, intercostal, or diaphragmatic and each of these types is either congenital or acquired. Acquired lung hernias that are up to 80% of total cases can be spontaneous, posttraumatic, postoperative, or pathologic (as a result of neoplastic or inflammatory processes).^[1-4]

Spontaneous lung hernias comprise a very small subgroup, with 30% of total reported cases in the literature.^[3-5] These hernias arise generally due to a combination of preexisting

weakness in the thoracic wall combined with an abnormal rise in intrathoracic pressure.^[1,2,6-9] The most common cause of increased intrathoracic pressure is chronic coughing – most frequently in chronic obstructive pulmonary disease (COPD) patients, vigorous sneezing, Valsalva maneuver, playing a wind instrument, as well as heavy lifting.^[2-6] The extreme obesity is considered as a predisposing factor of spontaneous lung hernia. Moreover, chronic steroid use and smoking are also accepted as risk factors for the thoracic wall weakness and lung herniation.

Our aim is to present a rare clinical case of spontaneous lung hernia – intercostal type after heavy lifting, complicated with huge soft tissue hematoma, single rib fracture, hemothorax, diaphragmatic laceration, and great omentum pleural herniation. The mechanism of arising and the treatment of intercostal lung hernias are discussed.

How to cite this article: Novakov IP, Hadzhiminev VD, Timonov PT. Complicated spontaneous intercostal lung hernia - A rare clinical case. Turk J Emerg Med 2021;21:221-4.

This is an open access journal, and articles are distributed under the terms of the Creative Commons Attribution-NonCommercial-ShareAlike 4.0 License, which allows others to remix, tweak, and build upon the work non-commercially, as long as appropriate credit is given and the new creations are licensed under the identical terms.

For reprints contact: WKHLRPMedknow_reprints@wolterskluwer.com

Submitted: 28-03-2021

Revised: 29-04-2021

Revised: 03-05-2021

Accepted: 04-05-2021

Published: 30-10-2021

ORCID:

IPN: 0000-0001-5853-7685

VDH: 0000-0001-6559-8945

PTT: 0000-0002-4606-2253

Address for correspondence:

Prof. Ivan Petkov

Novakov,

Peshersko Shosse 66,

Plovdiv 4000, Bulgaria.

E-mail: inovakov2003@yahoo.com

Case Presentation

A 46-year-old obese man (body mass index: 40.2) was presented to our emergency department with moderate left-sided chest pain that started immediately after heavy lifting 2 days before the examination. The patient had no history of trauma, surgical procedures in his thoracic wall, or COPD. His comorbidities were arterial hypertension, congestive heart failure, and type II diabetes mellitus. At the time of admission, the patient was alert and oriented. His vital signs were as follows: blood pressure – 140/90 mmHg, heart rate – 90 per minute, respiratory rate – 18 per minute, and body temperature – 36.7°C. Physical examination revealed a swelling of the left flank (from mid-thorax to the gluteus) with red-bluish colorization of the skin and tenderness on palpation [Figure 1]. On auscultation, diminished breath sounds on the left were established.

Chest X-ray presented stable intercostal lung herniation – through sixth intercostal space [Figure 2]. Subsequent chest computed tomography (CT) confirmed the stable left intercostal lung herniation. Moreover, hematoma of the left flank, displaced fracture of the seventh left rib, and fluid into the left costophrenic angle with a density of 21 Hounsfield units were found [Figure 3a and b]. The spirometry test was performed with volume of a FEV₁ of 2.42 L (64% of predictive) and FEV₁/FVC of 72%.

The patient was hospitalized and operated on the 2nd day of his hospitalization. Left mid-lateral thoracotomy under general anesthesia with intubation with a double-lumen endotracheal tube was performed. The incisional line was made over the side of the thoracic wall defect (through sixth intercostal space). Exploration of the left hemothorax revealed thoracic wall hematoma, lung herniation through the sixth intercostal space with compressed herniated part of the lung, minimal hemothorax in costophrenic angle (<150 ml), dislocated fracture of the left seventh rib-type “costochondral joint separation,” and laceration of the diaphragm (approximately 4 cm and close to esophageal hiatus), with herniation of a small portion of the great omentum into the pleural cavity.

Blood from costophrenic angle was sucked out. The herniated part of the great omentum was reponated back into the peritoneal cavity, and the defect of the diaphragm was closed by nonabsorbable interrupted sutures. The pleural cavity was irrigated with sterile saline solution. The thoracic cage was closed with pericostal sutures around the 6th and 7th ribs, after inserting a chest tube drain. Thoracic wall hematoma, along the incisional line, was cleaned, and the soft tissues were irrigated with povidone-iodine 10 % solution.

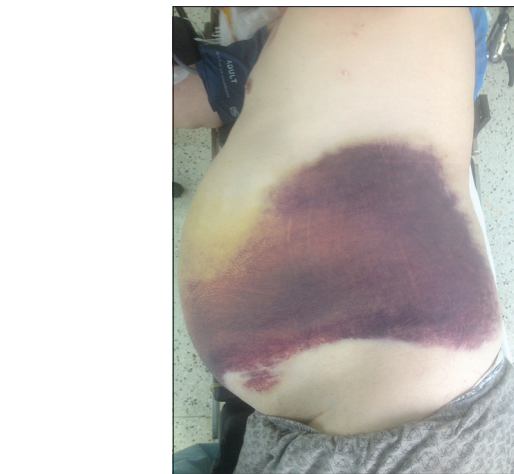

Figure 1: A huge left-sided flank hematoma

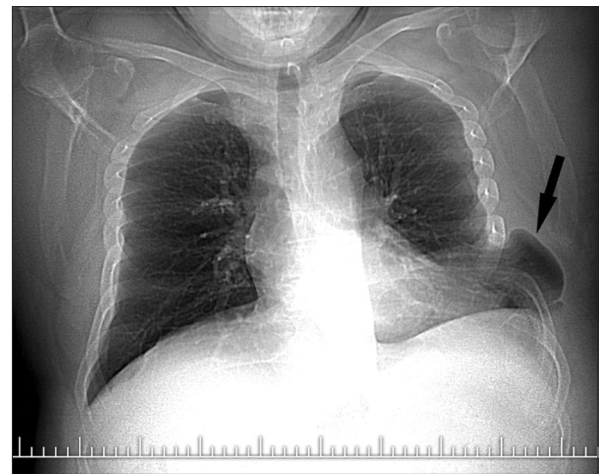


Figure 2: Initial chest radiograph: Presentation of lung herniation through sixth intercostal space (herniated lung is pointed by an arrow)

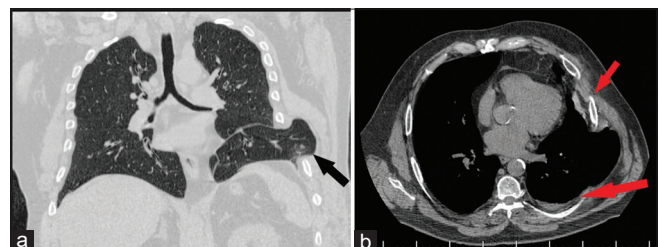


Figure 3: Chest computed tomography obtained 1 h after the initial chest radiograph: (a) herniated lung is pointed by an arrow; (b) the small arrow points the displaced fracture of seventh left rib and the large arrow points fluid into the left costophrenic angle

The patient was discharged on the 9th postoperative day in a good condition. Control chest CT 2 years after the operation found no deformation of the thorax or recurrence of the lung herniation.

Written informed consent was obtained from the patient for his anonymized information to be published.

Discussion

In majority of cases, spontaneous lung hernias are intercostal type.^[1,2] Predilection site for spontaneous intercostal lung herniation is parasternal area (cartilaginous part of the ribs). This area of thoracic cage due to the lack of overlapping muscular support by external intercostal muscles is a potential site of weakness. This is the reason why parasternal area is a predilection site of intercostal lung herniation. Furthermore, intercostal type of spontaneous lung hernias occurs more frequently in men, especially these with extreme obesity like in the case which we present.

Based on their clinical presentation, intercostal lung hernias are divided into asymptomatic and symptomatic. The latter are subdivided into uncomplicated (most of the cases) and complicated. The reported complications in spontaneous intercostal lung hernias are rib fractures, lung incarcerations, and infections.^[1-4] We find this case interesting because of the number and type of complications: a huge flank hematoma, single rib fracture, hemothorax, laceration of the diaphragm, and great omentum pleural cavity herniation.

Diagnosis of intercostal lung herniation is simply made on the basis of chest X-ray. Positive finding includes the presence of lung field outside the rib cage – “lung beyond rib sign.” Chest CT is helpful in determining the exact location and size of the hernia as well as the presence of associated complications.^[1-5] However, similarities between the tomographic density of the great omentum or clotted blood could be a reason for preoperative misdiagnosis of herniation of this solid abdominal organ into the thoracic cage.

It is unlikely for intercostal lung hernias to resolve spontaneously. There is also a very high risk of incarceration of the lung, especially in a small intercostal defect. Furthermore, intercostal hernias complicated with rib fractures are a risk factor for lung laceration. Early surgical repair is, therefore, the method of choice in the treatment of spontaneous intercostal lung hernias.^[10-14] This method has a low morbidity rate and ensures good postoperative result and excellent long-term prognosis, which was also demonstrated in the present case. Conservative management of intercostal lung hernias, with compressive pads and corsets, is recommended only for those patients with extremely high cardiovascular perioperative risk.

The basic concept of surgical repair of intercostal lung hernias includes reducing the hernia, approximation of the ribs, and stabilization of the intercostal space. The repair of intercostal lung hernia may be performed with or without the use of synthetic patch by conventional (thoracotomy)

or mini-invasive (thoracoscopic) approach.^[10-14] The conventional thoracotomy with only pericostal sutures for stabilization of the intercostal space was the method of choice in the presented case. Moreover, repair of the diaphragmatic defect was performed. The method of choice should be, however, strongly personalized in every single case.

Conclusion

We present a rare case of spontaneous intercostal lung hernia in obesity and heavy lifting considered as a predisposing and a precipitating factor. We find this as a case of interest because of the number and type of associated injuries: a huge flank soft tissue hematoma, single rib fracture, hemothorax, laceration of the diaphragm, and great omentum herniation into the pleural cavity. We also demonstrate low morbidity and good postoperative result by conventional surgery in intercostal lung herniation.

Author contribution statement

IN: Conceptualization, Resources, Supervision, Visualization, Writing – Original Draft, Writing – Review and Editing (equal).

VH, PT: Resources, Visualization, Writing – Original Draft, Writing – Review and Editing (equal).

Conflicts of interest

None declared.

Consent to participate

The authors certify that they have obtained all appropriate patient consent forms. In the form, the patient has given his consent for his images and other clinical information to be reported in the journal. The patient understands that name and initials will not be published and due efforts will be made to conceal the identity, but anonymity cannot be guaranteed.

Funding

None declared.

References

1. Bhalla M, Leitman BS, Forcade C, Stern E, Naidich DP, McCauley DI. Lung hernia: Radiographic features. *AJR Am J Roentgenol* 1990;154:51-3.
2. Weissberg D, Refaely Y. Hernia of the lung. *Ann Thorac Surg* 2002;74:1963-6.
3. Dahlkemper CL, Greissinger WP. Spontaneous lung herniation after forceful coughing. *Am J Emerg Med* 2020;38:851.e5-6.
4. Tack D, Wattiez A, Schtickzelle JC, Delcour C. Spontaneous lung herniation after a single cough. *Eur Radiol* 2000;10:500-2.
5. Abouda M, Triki M. Intercostal lung herniation. *J Pediatr* 2016;169:327.
6. Sulaiman A, Cottin V, De Souza Neto EP, Orsini A, Cordier JF, Gamondes JP, *et al.* Cough-induced intercostal lung herniation requiring surgery: Report of a case. *Surg Today* 2006;36:978-80.
7. Getzoff A, Shaves S, Carter Y, Foy H. Traumatic lung herniation. *AJR Am J Roentgenol* 1999;172:1032.
8. Ranu H, Jackson M. Apical lung herniation. *Thorax* 2011;66:740.
9. Mason K, Riordan RD. Lung herniation: An unusual cause of

Novakov, et al.: Intercostal lung hernia

- dysphagia. Ear Nose Throat J 2013;92:561-2.
10. Chiang TY, Yin MF, Yang SM, Chen KC. Thoracoscopic management of incarcerated lung herniation after blunt chest trauma: A case report and literature review. J Thorac Dis 2017;9:E253-7.
 11. Wani AS, Kalamkar P, Alhassan S, Farrell MJ. Spontaneous intercostal lung herniation complicated by rib fractures: A therapeutic dilemma. Oxf Med Case Reports 2015;2015:378-81.
 12. Kara HV, Javidfar J, D'Amico TA. Spontaneous herniation of the lung and diaphragm treated with surgical repair. Ann Thorac Surg 2015;99:1821-3.
 13. García RT, Moscoso ET, Ligonio BM. Successful delayed repair of lung evisceration secondary to stab wound. Rev Inst Nal Enf Resp Mex 2008;21:35-7.
 14. Kolará M, Topraka A, Winthropá A, Sly L, Soboleski D. Surgical vs. nonsurgical management of post-traumatic intercostal lung herniation in children. J Pediatric Surg Case Rep 2018;28:51-8.