



Access this article online

Quick Response Code:



Website:

www.turkjemergmed.org

DOI:

10.4103/2452-2473.329626

Case Report

A successful treatment with intravenous lipid emulsion therapy in a child with verapamil poisoning

Merve Havan^{1*}, Tanıl Kendirli¹, Serhan Özcan¹, Melih Timuçin Doğan², Ahmet Onur Yiğit¹, Tayfun Uçar²

Departments of ¹Pediatric Intensive Care and ²Pediatric Cardiology, School of Medicine, Ankara University, Ankara, Turkey

Abstract:

In recent years, intravenous lipid emulsion therapy (ILE) was used for lipophilic drug intoxications, and successful results were obtained. In the literature, there is a small number of reported cases about verapamil intoxication and ILE therapy in the pediatric age group. We used ILE therapy in a 14-year-old girl with verapamil intoxication in the 2nd h of the pediatric intensive care unit stay, before using traditional treatments such as glucagon and hyperinsulinemic euglycemia. She had resistant bradycardia and hypotension which was unresponsive to inotropic agents and a successful result was obtained after using ILE treatment. We believe our report may contribute to the early use of ILE therapy for toxicity with calcium channel blockers such as verapamil in pediatric patients.

Keywords:

Children, intoxication, lipid emulsion therapy, verapamil

Submitted: 23-02-2021

Revised: 06-04-2021

Revised: 07-04-2021

Revised: 12-04-2021

Revised: 08-05-2021

Revised: 16-05-2021

Accepted: 17-05-2021

Published: 30-10-2021

ORCID:

MH: 0000-0003-3431-7906

TK: 0000-0001-9458-2803

SÖ: 0000-0003-4465-6063

MTD: 0000-0003-3565-8606

OY: 0000-0003-4373-7021

TU: 0000-0003-1206-5103

Address for correspondence:

Dr. Merve Havan,
Division of Pediatric
Critical Care Medicine,
Ankara University Faculty
of Medicine, Ankara,
Turkey.

E-mail: merve-havan@outlook.com

Introduction

In recent years, intravenous lipid emulsion therapy (ILE) has been frequently used in the intoxications of anesthetic and lipophilic drugs after animal experiments. Initial studies were done in the late 1990s.^[1] ILE therapy began to be used for therapeutic purposes in the systemic toxicity of local anesthetic drugs in 2006, and then it was used for lipophilic drug toxicity, and successful results have been reported in intoxications with calcium channel blockers (CCBs), beta-blockers, neuroleptics, antidepressants, and anticonvulsants.^[2,3]

Hypotension and bradycardia are the most common symptoms in CCB intoxication. Metabolic acidosis and hyperglycemia are other common symptoms. In verapamil intoxication, there is no known antidote.

This is an open access journal, and articles are distributed under the terms of the Creative Commons Attribution-NonCommercial-ShareAlike 4.0 License, which allows others to remix, tweak, and build upon the work non-commercially, as long as appropriate credit is given and the new creations are licensed under the identical terms.

For reprints contact: WKHLRPMedknow_reprints@wolterskluwer.com

Gastrointestinal decontamination is the first-line therapy. Intravenous calcium supplements, glucagon, hyperinsulinemic euglycemia (HIE) treatment, and in recent years, lipid emulsion therapy are recommended treatment methods in verapamil intoxication.^[4]

Here, we would like to report the early use of ILE therapy in verapamil intoxication in a 14-year-old girl who was followed with resistant hypotension and bradycardia in our pediatric intensive care unit (PICU).

Case Report

A 14-year-old girl was admitted to the pediatric emergency room with complaints of vomiting and dizziness. The patient stated that she had ingested 40 tablets verapamil (contains 120 mg verapamil hydrochloride in each tablet) 10 h before the emergency service admission. The patient

How to cite this article: Havan M, Kendirli T, Özcan S, Doğan MT, Yiğit AO, Uçar T. A successful treatment with intravenous lipid emulsion therapy in a child with verapamil poisoning. Turk J Emerg Med 2021;21:217-20.

underwent continuous cardiac monitoring. Her serial electrocardiography (ECGs) were obtained. On her physical examination, her body weight was 60 kg and her height was 157 cm. She was lethargic, her arterial blood pressure (BP), heart rate, respiration rate, and body temperature were measured as 57/32 mmHg, 50/min, 14/min, and 36.2°C, respectively. In the emergency department, gastric lavage and active charcoal treatment were not performed because she received the drug 10 h before the admission. 20 ml/kg 0.9% saline infusion has been given to the patient two times in the emergency department. The patient was taken to the PICU because her bradycardia and hypotension were resistant despite treatment. A central venous catheter was inserted quickly and 2500 ml/m² hydration was started. In the laboratory analyses, complete blood count, renal function tests, serum electrolytes, and arterial blood gas analyses were taken, and all the results were within normal limits apart from elevated lactate levels (5.2 mmol/L). Hyperglycemia was not found in the patient's blood glucose monitoring. In our follow-up, her general condition was poor and lethargic; bradycardia and ventricular extrasystoles were seen in the ECG [Figure 1]. She was in cardiogenic shock and dopamine infusion, at a rate of 10 mcg/kg/min was started, and calcium gluconate was given for CCB toxicity but her vital parameters did not change. Then, norepinephrine infusion therapy (0.1 mcg/kg/min) was started because she had peripheral vasodilatation symptoms and flushing. At the 2nd h of the patient's PICU hospitalization, we considered it appropriate to start ILE treatment, as the patient's hypotension and bradycardia continued, despite increased doses of inotropic drugs and calcium support. Intravenous lipid infusion (20% Intralipid) therapy was started at a rate of 1.5 ml/kg for 2 h. Half an hour after starting the ILE treatment, the patient's rhythm returned to the sinus rhythm, the ventricular extrasystoles disappeared on the patient's ECG and her arterial BP began to improve. The patient's BP was 79/52 mmHg when we started treatment. BPs were measured at 30 min, 1 h, and 2 h after the treatment had started, and the BPs were 84/56, 90/61,

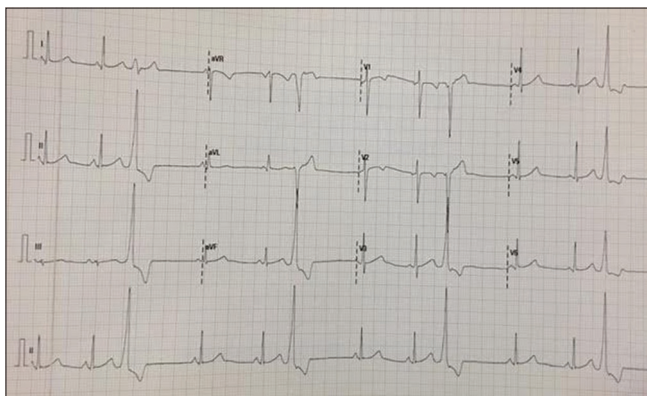


Figure 1: Sinus bradycardia and ventricular extrasystoles on electrocardiography of the patient before lipid emulsion therapy

and 92/67 mmHg, respectively. Vital signs of the patient before and after ILE treatment are given in Table 1. After treatment, her inotropic drugs were gradually reduced within 8 h, and her consciousness began to recover very quickly. On the 2nd day of the intensive care stay, the patient was transferred to the cardiology service with complete neurological recovery and no organ failure. She was discharged from the hospital on the 4th day of admission. Detailed informed consent was obtained from the patient's parents in this case report.

Discussion

Verapamil is a nondihydropyridine CCB that is used in the treatment of arrhythmias, hypertension, and angina pectoris. Verapamil selectively blocks L-type calcium channels in the myocardium which are responsible for myocardial and vascular smooth muscle contractility.^[5] Verapamil toxicity causes peripheral vasodilation, hypotension, bradycardia, metabolic acidosis, hyperglycemia, congestive heart failure, pulmonary edema, and cardiac arrest. There is no specific antidote for verapamil overdose, and extracorporeal removal by hemodialysis is not effective. Orogastric lavage is useful if performed in the first 2 h after taking the drug, but vagal stimulation may exacerbate CCB-induced bradycardia and hypotension. We did not perform gastric lavage on our patient because she came to the emergency room 10 h after taking the drug, and we thought that orogastric lavage would not be beneficial and could worsen the patient's symptoms with vagal system activation.

Intravenous calcium supplements have been used for the treatment of cardiac side effects in verapamil toxicity. Glucagon has chronotropic and inotropic effects but is not effective in the recovery of bradycardia. HIE is a successful treatment for hypotension, hyperglycemia, and metabolic acidosis but has not been shown to have sufficient effect in the treatment of bradycardia, heart block, and intraventricular conduction delay.^[6] Our patient was in hypotensive shock, and she had refractory bradycardia. Despite intravenous saline bolus treatment, calcium gluconate, and high doses of inotropic agents, the patient's bradycardia and hypotension did not improve. Due to the absence of hyperglycemia during her admission and the fact that her main symptoms are

Table 1: The patient's vital signs before and after intravenous lipid emulsion therapy

Vital signs	Emergency service admission	PICU admission	Before ILE therapy	After ILE therapy (2 nd h)
Blood pressure (mmHg)	57/32	67/48	79/57	92/67
Heart rate (/min)	50	51	56	64

ILE=Intravenous lipid emulsion, PICU=Pediatric intensive care unit

secondary to cardiac pathology, we did not give HIE treatment as a priority.

In recent years, ILE therapy has been used in the emergency department for life-threatening drug intoxications.^[3] Although the effect of ILE therapy in the treatment of drug toxicity is still not fully known, two main mechanisms are emphasized in particular. First, the sweeping/portioning effect which is known as the lipid sink/shuttle phenomenon, and second, its direct cardiovascular effect since it acts on myocytes.^[2] In an *in vitro* study, traditional treatments such as calcium supplements, glucagon, and insulin used in verapamil toxicity were shown to not affect L-type calcium channels, but ILE therapy directly affects L-type calcium channels, restoring myocyte contractility.^[7] For this reason, we planned to give ILE treatment after calcium support and inotropic agents, as we thought we would see more benefits from ILE treatment than glucagon and HIE.

In the literature, there is no accurate information about when to start ILE treatment for lipophilic drug toxicity, what dose to apply, and whether bolus treatment or continuous infusion is more useful.^[2] Previous publications on the use of ILE therapy in patients with verapamil poisoning are presented in detail in Table 2. There are only a few cases related to the use of ILE therapy in verapamil poisoning, and when these cases are examined, it has been reported that ILE therapy benefits some and does not provide the expected benefit in others [Table 2]. Furthermore, there are not enough publications on the use of ILE therapy in verapamil poisoning in pediatric patients. In a study that identified 14 cases, all patients were given different doses of bolus and/or continuous ILE therapy, and treatment doses were reported to vary according to the experience of

clinicians.^[14] In another study, blood verapamil levels were measured after poisoning, and the measured level was reported to be decreased after ILE treatment.^[11] In our study, we were unable to measure blood verapamil levels. In the literature, there is no definitive data on the administration dose of ILE therapy in the pediatric age group. We administered 1.5 g/kg 20% lipid solution as an intravenous infusion for 2 h, avoiding giving a bolus dose, because our patient was a child, and we thought that lipid treatment at a bolus dose might have side effects.

ILE treatment also can have serious side and adverse effects. In adults, hyperlipidemia, increased bleeding tendency, hypokalemia, hypophosphatemia, local thrombophlebitis, acute lung damage, hemolysis, and acute pancreatitis have been reported.^[14] In our case, we did not see any complication about medication.

ILE treatment was stated to be beneficial in lipophilic drug poisoning. In the literature, it is recommended to use ILE therapy after standard treatment protocols (calcium support, glucagon, and HIE) for verapamil poisoning and to use extracorporeal treatment methods if the benefit is still not achieved. We applied ILE therapy to our case before applying much more invasive extracorporeal treatment methods such as hemoperfusion and extracorporeal membrane oxygenation. After starting ILE treatment, the patient's clinical manifestations quickly improved, and we began to reduce the infusion doses of inotropic agents, and the patient's consciousness quickly improved.

Conclusion

This case report may be useful to show that good results can be achieved using early-stage ILE therapy

Table 2: Recent publications reporting the use of intravenous lipid emulsion therapy in verapamil poisoning

Publication year (references)	Age (years)/gender	Verapamil overdose (mg)	ILE dose	Additional therapies	Response to ILE therapy
2009 ^[8]	15/-	4200	Not obtained	Calcium gluconate, HIE, ECMO, CVVH	No change
2009 ^[4]	32/male	13,440	100 ml IV bolus 0.5 ml/kg/h infusion	Norepinephrine, calcium gluconate, glucagon	Resolution of hypotension
2011 ^[9]	39/female	4080	100 ml IV bolus 0.5 ml/kg/h infusion	Calcium gluconate, glucagon, norepinephrine	Resolution of hypotension
2011 ^[10]	41/female	19,200	100 ml IV bolus 0.5 ml/kg/h infusion	Calcium, dopamine, isoproterenol, norepinephrine, epinephrine, vasopressin, HIE, CVVH, nitric oxide	Resolution in multisystem function
2011 ^[11]	47/male	6300	100 ml IV bolus 150 ml IV/15 min	Atropine, glucagon, calcium, HIE, norepinephrine, dopamine, vasopressin	Resolution of cardiac function
2014 ^[12]	51/female	9600	100 ml IV bolus 0.2 ml/kg/min infusion	Norepinephrine, epinephrine, calcium gluconate, CVVH, ECMO	Resolution of ARDS
2015 ^[13]	24/female	7200	Intraosseously, dose not obtained	Glucagon, HIE, calcium gluconate, norepinephrine	No change, death

ARDS=Acute respiratory distress syndrome, CVVH=Continuous venovenous hemofiltration, ECMO=Extracorporeal membrane oxygenation, HIE=Hyperinsulinemic euglycemia, IV=Intravenous, ILE=Intravenous lipid emulsion

in pediatric patients with verapamil poisoning. As the number of studies on ILE use in children increases, this method of treatment will be used more often in lipophilic drug poisoning.

Acknowledgment

In this case report everyone who contributed to this manuscript is listed as an author.

Author contributions statement

Merve Havan: Conceptualization (lead); writing – original draft (lead); Methodology (lead). Tanıl Kendirli: Supervision (lead); Visualization (lead). Serhan Özcan: Methodology (lead); Resources; Writing – original draft (supporting). Melih T. Doğan: Resources (supporting). Onur Yiğit: Resources Writing – original draft (supporting). Tayfun Uçar: Writing – review and editing (equal).

Conflicts of interest

None Declared.

Consent to participate

The authors certify that they have obtained all appropriate patient consent forms. In the form, the parents have given their consent for images and other clinical information to be reported in the journal. The parents understand that names and initials will not be published, and due efforts will be made to conceal identity, but anonymity cannot be guaranteed.

Financial support and sponsorship

None.

References

1. Weinberg GL, VadeBoncouer T, Ramaraju GA, Garcia-Amaro MF, Cwik MJ. Pretreatment or resuscitation with a lipid infusion shifts the dose-response to bupivacaine-induced asystole in rats. *Anesthesiology* 1998;88:1071-5.
2. Robben JH, Dijkman MA. Lipid therapy for intoxications. *Vet Clin North Am Small Anim Pract* 2017;47:435-50.
3. Jamaty C, Bailey B, Larocque A, Notebaert E, Sanogo K, Chauny JM. Lipid emulsions in the treatment of acute intoxication: A systematic review of human and animal studies. *Clin Toxicol* 2010;48:1-27.
4. Young AC, Velez LI, Kleinschmidt KC. Intravenous fat emulsion therapy for intentional sustained-release verapamil overdose. *Resuscitation* 2009;80:591-3.
5. Hofer CA, Smith JK, Tenholder MF. Verapamil intoxication: A literature review of overdoses and discussion of therapeutic options. *Am J Med* 1993;95:431-8.
6. Shepherd G, Klein-Schwartz W. High-dose insulin therapy for calcium-channel blocker overdose. *Ann Pharmacother* 2005;39:923-30.
7. Kryshnal DO, Dawling S, Seger D, Knollmann BC. *In vitro* studies indicate intravenous lipid emulsion acts as lipid sink in verapamil poisoning. *J Med Toxicol* 2016;12:165-71.
8. Aaronson PM, Wassil K, Kunisaki TA. Hyperinsulinemic euglycemia, continuous venovenous hemofiltration, and extracorporeal life support for severe verapamil poisoning: Case report. *Clin Toxicol* 2009;47:742.
9. Franxman TJ, Al-Nabhan M, Cavallazzi RS, Speak AJ. Lipid emulsion therapy for verapamil overdose. *Ann Intern Med* 2011;154:292.
10. Liang CW, Diamond SJ, Hagg DS. Lipid rescue of massive verapamil overdose: A case report. *J Med Case Rep* 2011;5:399.
11. French D, Armenian P, Ruan W, Wong A, Drasner K, Olson KR, et al. Serum verapamil concentrations before and after Intralipid® therapy during treatment of an overdose. *Clin Toxicol (Phila)* 2011;49:340-4.
12. Martin C, Gonzalez H, Ruiz S, Ribes D, Franchitto N, Minville V. Acute respiratory distress syndrome following verapamil overdose treated with intravenous lipid emulsion: A rare life-threatening complication. *Ann Fr Anesth Reanim* 2014;33:e101-2.
13. Sampson CS, Bedy SM. Lipid emulsion therapy given intraosseously in massive verapamil overdose. *Am J Emerg Med* 2015;33:1844.e1.
14. Presley JD, Chyka PA. Intravenous lipid emulsion to reverse acute drug toxicity in pediatric patients. *Ann Pharmacother* 2013;47:735-43.