



Access this article online

Quick Response Code:



Website:

[www.turkjemergmed.org](http://www.turkjemergmed.org)

DOI:

10.4103/2452-2473.297469

## Case Report

# Reexpansion pulmonary edema: A rare complication of pneumothorax drainage

Shivani Sarada, Ankur Verma\*, Sanjay Jaiswal, Wasil Rasool Sheikh

Department of Emergency Medicine, Max Super Speciality Hospital, New Delhi, India

\*Corresponding author

### Abstract:

Among all the noncardiac causes of pulmonary edema, unilateral reexpansion pulmonary edema is one of the rarest complication of expansion of a collapsed lung. It is largely unknown and a potentially fatal complication. We present the case of a 51-year-old gentleman who presented to our emergency department with shortness of breath. X-ray revealed significant right-sided pneumothorax with associated collapse of the right lung. An intercostal tube was inserted into the right 5<sup>th</sup> intercostal space and a repeat X-ray revealed well-expanded lung field. Soon, the patient developed increased shortness of breath and hypoxia. Repeat X-ray was suggestive of pulmonary edema. He was started on noninvasive positive pressure ventilation and responded well to it. Emergency physicians should have a high index of suspicion and initiate early management of reexpansion pulmonary edema in patients suffering from pneumothoraces which have undergone drainage.

### Keywords:

Chest tube, pneumothorax, reexpansion pulmonary edema

## Introduction

Among all the noncardiac causes of pulmonary edema, unilateral reexpansion pulmonary edema (REPE) is one of the rarest complication of expansion of a collapsed lung.<sup>[1]</sup> REPE occurring after a pneumothorax has been drained is still under recognized and under reported.<sup>[2]</sup> Since REPE has a high mortality rate of 21%, its recognition at the right time cannot be emphasized enough.<sup>[3]</sup> Here, we present a case of unilateral ipsilateral REPE after chest tube insertion in a patient with massive pneumothorax.

## Case Report

A lean 51-year-old gentleman presented

This is an open access journal, and articles are distributed under the terms of the Creative Commons Attribution-NonCommercial-ShareAlike 4.0 License, which allows others to remix, tweak, and build upon the work non-commercially, as long as appropriate credit is given and the new creations are licensed under the identical terms.

to our emergency department (ED) with shortness of breath since 3 days. The patient had no comorbidities and was a nonsmoker. On arrival, his blood pressure was recorded as 136/90 mmHg, heart rate of 103/min, respiratory rate of 19/min, oxygen saturation (SPO<sub>2</sub>) on room air of 98%, random blood sugar of 104 mg/dL, and was afebrile. On systemic examination, the patient was found to have reduced breath sounds in the right hemithorax. No adventitious sounds could be heard. The rest of the systemic examination was normal. Routine blood investigations revealed a total leukocyte count of  $21.4 \times 10^9/L$  with a neutrophil count of 84%. Chest X-ray revealed significant right-sided pneumothorax with associated collapse of the right lung [Figure 1].

An intercostal tube (FR 28) was inserted into the right 5<sup>th</sup> intercostal space. A repeat X-ray revealed well-expanded lung field

**How to cite this article:** Sarada S, Verma A, Jaiswal S, Sheikh WR. Reexpansion pulmonary edema: A rare complication of pneumothorax drainage. Turk J Emerg Med 2020;20:196-8.

For reprints contact: [reprints@medknow.com](mailto:reprints@medknow.com)

Submitted: 05-03-2020

Revised: 13-05-2020

Accepted: 19-05-2020

Published: 07-10-2020

ORCID:

SS: 0000-0002-5526-3778

AV: 0000-0001-9524-9164

SJ: 0000-0001-5333-8230

WRS: 0000-0001-8479-

7632

Address for  
correspondence:

Dr. Ankur Verma,  
Flat 801, 8<sup>th</sup> Floor, Tower  
8, Unitech Harmony,  
Nirvana Country, Sector  
50, Gurgaon, Haryana,  
India.

E-mail: [anksv25@gmail.com](mailto:anksv25@gmail.com)

[Figure 2]. The patient was maintaining normal vitals when after 1 h, he suddenly developed severe shortness of breath and became hypoxic with an SPO<sub>2</sub> of 74% on room air and tachypneic with a respiratory rate of 33/min. On examination, the patient had developed coarse right-sided crepitations. He was started on high-flow oxygen via face mask, and an urgent X-ray chest, electrocardiogram (ECG), and blood gas were ordered. The blood gas revealed Type 1 respiratory failure with a PO<sub>2</sub> of 41 mmHg. ECG revealed a normal sinus rhythm and X-ray was suggestive of alveolar opacities in the right upper and mid zones suggestive of unilateral pulmonary edema [Figure 3]. The patient was started on bilevel positive airway pressure (BiPAP) support which brought the SPO<sub>2</sub> to 92%.

Based on the findings and clinical presentation, a diagnosis of spontaneous right pneumothorax with reexpansion unilateral pulmonary edema was made. The patient was transferred to the intensive care unit and kept on BiPAP support. After 6 days, the patient's X-ray revealed a normal study and the patient was discharged home in a stable condition.

## Discussion

Our patient suffered from REPE after a chest tube was inserted to manage the spontaneous massive pneumothorax he had. The patient had become tachypneic and hypoxic, but responded well to noninvasive ventilation. REPE is usually a self-limiting disorder and mostly requires airway and circulation management. However, a 21% mortality rate cannot be ignored and emergency physicians should be able to recognize this seemingly benign yet fatal complication.

The exact mechanism of REPE is still not understood. REPE appears to be due to increased permeability of the pulmonary vasculature. High protein content found in edema fluid indicates that it is leakiness of the capillaries rather than an increased hydrostatic pressure difference that leads to the edema. Lung injury could also occur due to reperfusion and oxygen free radical formation in the collapsed lung.<sup>[4]</sup> Young adults, female sex, greater degree and longer duration of lung collapse, a reexpansion of lung in <10 min, use of negative pressure during treatment, and evacuation volume more than 2000 ml have been shown to be at a higher risk for developing reexpansion pulmonary edema. Signs and symptoms include sudden onset of breathing difficulty, tachypnea, hypoxia, and tachycardia, usually within 1–2 h of intercostal chest drainage. No studies have been performed comparing the different methods of draining a pneumothorax, but some papers may suggest that the technique of draining

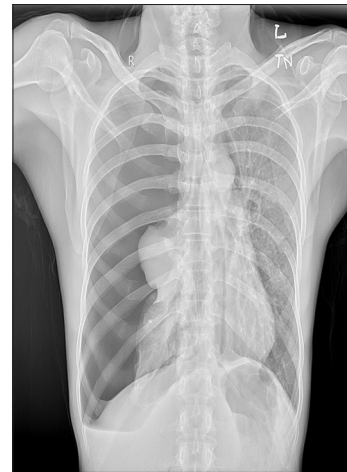

Figure 1: X-ray chest showing significant right-sided hydropneumothorax with associated collapse of the right lung

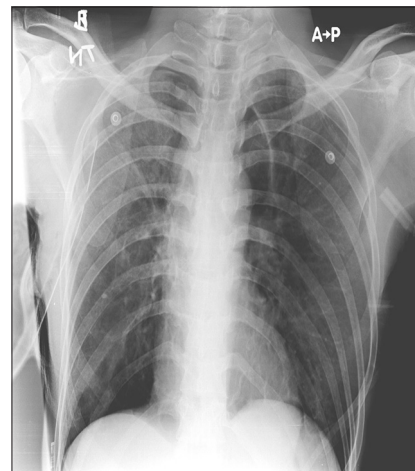

Figure 2: Follow up X-ray chest showing well-expanded lung fields on both sides

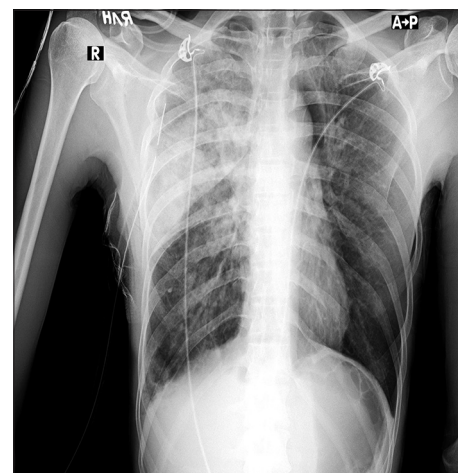


Figure 3: X-ray chest showing alveolar opacities in the right lung suggestive of pulmonary edema

a pneumothorax might influence the development of REPE.<sup>[5]</sup> It is recommended not to drain more than 1 liter of fluid or air at once and to use water

valves instead of suction. 1200–1800 mL should be the maximum volume of air or fluid to be drained as per estimates. It is advised to stop drainage when the patient starts coughing, as it might be a first sign of pulmonary edema formation.<sup>[6]</sup> The treatment of REPE is supportive and consists of oxygen, BiPAP, or CPAP support. Verhagen *et al.* described a case of REPE in a traumatic pneumothorax. The patient was kept on CPAP and recovered within a week.<sup>[6]</sup> In some cases, intubation and mechanical ventilation with positive end expiratory pressure (PEEP) will be necessary. Since the cause of pulmonary edema is not cardiogenic, use of diuretics needs to be avoided.

## Conclusion

REPE remains a largely unknown complication, but is potentially fatal. It occurs in <1% of cases where a lung has been rapidly expanded postchest tube drainage.<sup>[7]</sup> It would be prudent for emergency physicians to suspect and initiate early management of REPE in patients suffering from pneumothoraces which have undergone drainage.

### Consent to participate

The authors certify that they have obtained all appropriate patient consent forms. In the form, the patient has given his consent for his images and other clinical information to be reported in the journal. The patient understands that name and initials will not be published

and due efforts will be made to conceal identity, but anonymity cannot be guaranteed.

### Funding

None declared.

### Author contributions

Sarda S is the principal author. All other coauthors have contributed toward the critical feedback, literature review, and proof reading for the manuscript.

### Conflicts of interest

None declared.

## References

1. Phillips SF, Neiman HL, Reeder MM. Noncardiac causes of pulmonary edema. *JAMA* 1975;234:531.
2. Aujayeb A, Green NJ. Re-expansion Pulmonary Oedema in Pneumothorax. *BMJ Case Rep* 2019;12:e229303.
3. Mahfood S, Hix WR, Aaron BL, Blaes P, Watson DC. Reexpansion pulmonary edema. *Ann Thorac Surg* 1988;45:340-5.
4. Janmeja AK, Mohapatra PR, Saini MS, Khurana A. Reexpansion pulmonary edema A case report. *Lung India* 2007;24:72-4.
5. Sohara Y. Reexpansion pulmonary edema. *Ann Thorac Cardiovasc Surg* 2008;14:205-9.
6. Verhagen M, van Buijtenen JM, Geeraedts LM Jr., Reexpansion pulmonary edema after chest drainage for pneumothorax: A case report and literature overview. *Respir Med Case Rep* 2015;14:10-2.
7. Petiot A, Tawk S, Ghaye B. Re-expansion pulmonary oedema. *Lancet* 2018;392:507.