



Access this article online

Quick Response Code:



Website:

[www.turkjemergmed.org](http://www.turkjemergmed.org)

DOI:

10.4103/2452-2473.290068

## Case Report

# A rare case of intestinal obstruction: Sclerosing encapsulating peritonitis of unknown cause

Jeong Ho Kang\*

Department of Emergency Medicine, Jeju National University School of Medicine, Jeju-do, Republic of Korea

\*Corresponding author

### Abstract:

Sclerosing encapsulating peritonitis (SEP) is characterized by the partial or complete enclosing of the small intestines by a thick fibro-collagenous membrane, which can cause recurrent intestinal obstruction. SEP is a clinically rare disease, and the major risk factor is peritoneal dialysis (PD). Early diagnosis of SEP is an important factor in the patient's prognosis, but it is clinically difficult. A 52-year-old woman visited the emergency department (ED) with a 2-day history of abdominal pain and vomiting. She had a history of liver cirrhosis with chronic hepatitis B, but no history of PD, and she underwent a biopsy of the peritoneum by laparoscopy a month ago. On physical examination, there were peritoneal irritation signs on the right lower quadrant (RLQ). Abdominal computed tomography (CT) showed dilated small intestinal loops clustered in the RLQ, which were surrounded by a sac-like, thick fibrous membrane. Based on CT findings, small intestinal obstruction due to SEP was early diagnosed in the ED. Emergency physicians should include SEP in the differential diagnosis of the cause of intestinal obstruction. Abdominal CT is a useful modality for the early diagnosis of SEP in the ED.

### Keywords:

Abdominal cocoon, sclerosing encapsulating peritonitis, peritoneal sclerosis

## Introduction

Sclerosing encapsulating peritonitis (SEP) is characterized by a progressive, intraperitoneal inflammatory process, leading to intestinal obstruction through obliteration of the peritoneal cavity or through adhesions. SEP is a rare disease, but life-threatening with a mortality of 60%–93%. Although SEP develops most often associated with peritoneal dialysis (PD), other causes should also be considered. Early diagnosis of SEP is an important factor in the treatment and prognosis of the patient.<sup>[1]</sup> This case report presents a rare case of small intestinal obstruction due to

SEP, diagnosed early in the emergency department (ED).

## Case Report

A 52-year-old woman visited the ED with a 2-day history of abdominal pain, nausea, and vomiting. Besides, the patient complained that the preexisting abdominal distention and constipation worsened. In the past medical history, the patient was being treated in the hepatology department for chronic hepatitis B with liver cirrhosis (LC). However, the patient had no history of PD, peritoneovenous shunting (PVS), abdominal surgery, abdominal tuberculosis, or systemic inflammatory disorders. The patient had undergone two times paracentesis in the past year, and the last

This is an open access journal, and articles are distributed under the terms of the Creative Commons Attribution-NonCommercial-ShareAlike 4.0 License, which allows others to remix, tweak, and build upon the work non-commercially, as long as appropriate credit is given and the new creations are licensed under the identical terms.

**How to cite this article:** Kang JH. A rare case of intestinal obstruction: Sclerosing encapsulating peritonitis of unknown cause. Turk J Emerg Med 2020;20:152-5.

For reprints contact: [reprints@medknow.com](mailto:reprints@medknow.com)

Received: 14-03-2020

Accepted: 23-04-2020

Published: 18-07-2020

ORCID:

JHK: 0000-0002-0108-0247

### Address for correspondence:

Dr. Jeong Ho Kang,  
Department of  
Emergency Medicine,  
Jeju National University  
School of Medicine,  
15, Aran 13-Gil, Jeju-si,  
Jeju-do 63241,  
Republic of Korea.  
E-mail: [sivakjh1234@  
gmail.com](mailto:sivakjh1234@gmail.com)

**Kang: Sclerosing encapsulating peritonitis**

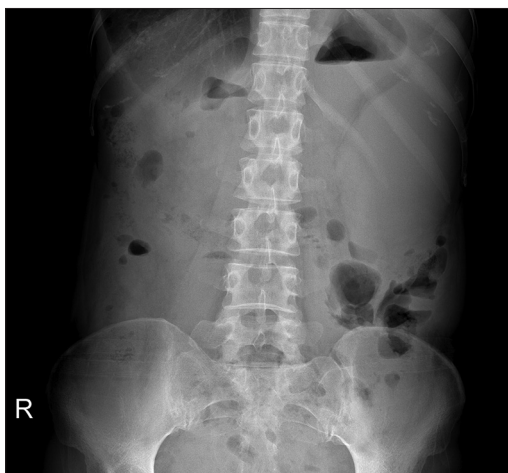paracentesis was received 3 months ago. There was no evidence of spontaneous bacterial peritonitis (SBP) on the ascites culture. Three months ago, the patient was taken abdominal computed tomography (CT) to differentiate the cause of recurrent abdominal pain. The CT findings revealed diffuse peritoneal thickening and paralytic small bowel ileus with moderate amounts of ascites, suggesting tumorous conditions or primary peritonitis. For differential diagnosis, she underwent a biopsy of the peritoneum by laparoscopy a month ago. On operative findings, the small and large intestines partially adhered to the peritoneal wall, but the abdominal cocoon pattern was not observed. There was no evidence of tumor on tissue biopsy of the peritoneum, and *Mycobacterium tuberculosis*/nontuberculous mycobacterium polymerase chain reaction test was negative. Also, there was no evidence of SBP on ascites culture.

At the time of arrival in the ED, her blood pressure was 128/51 mmHg, body temperature was 36.6°C, pulse rate was 90 beats/min, and respiratory rate was 20 breaths/min. Physical examination revealed tenderness and rebound tenderness on the right lower quadrant (RLQ) with heightened intestinal sounds. Laboratory tests showed as follows: leukocyte count: 2,300/ $\mu$ L (reference, 4,000–10,000/ $\mu$ L), platelet count: 63,000/ $\mu$ L (reference, 150,000–450,000/ $\mu$ L), C-reactive protein level: 3.93 mg/dL (reference, <0.3 mg/dL), albumin level: 3.1 g/dL (reference, 3.8–5.3 g/dL), total bilirubin level: 1.6 mg/dL (reference, 0.2–1.2 mg/dL), and prothrombin time International normalized ratio (INR): 1.52 INR (reference, 0.88–1.20 INR). Moreover, the results of other laboratory tests were within the normal limits. Abdominal X-ray did not show any specific findings suggestive of intestinal obstruction [Figure 1]. Because the patient had persistent peritoneal irritation signs, an abdominal CT was conducted to differentiate the cause of abdominal pain. Abdominal CT showed dilated small

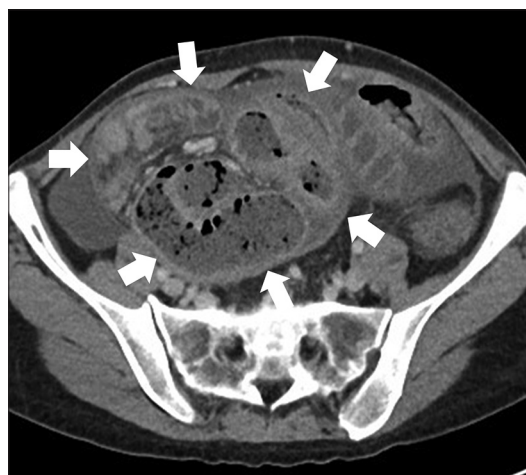intestinal loops clustered in the RLQ, which were encased by a thick, sac-like membrane [Figures 2 and 3]. Based on the abdominal CT findings, SEP with closed-loop small intestinal obstruction was strongly suspected and consulted with a general surgeon. He suggested that conservative treatment would be more appropriate for the patient until the small intestinal obstruction progressed to complete obstruction. In our ED, conservative treatment of intestinal obstruction such as bowel decompression with a nasogastric tube and fluid therapy was performed, and the patient was admitted to the hepatology department. During admission, she was successfully treated with conservative treatment and parenteral nutrition, and on the 7 days of admission, symptoms of intestinal obstruction improved, and she was discharged. However, until recently, she was hospitalized twice more due to recurrent bowel obstruction. Surgical treatment is currently not considered at the discretion of the general surgeon. This case was written according to the Helsinki Declaration and approved by the Institutional Review Board of Jeju National University Hospital (IRB no. 2020-02-008). The requirement for informed consent was waived by the institutional review board.

**Discussion**

SEP is characterized by partial or complete enclosing of the small intestines by a thick fibro-collagenous membrane, which gives the appearance of a cocoon within the peritoneal cavity. Because of this feature, it is also known as “abdominal cocoon” and “encapsulating peritoneal sclerosis.” SEP is classified as primary or secondary depending on the underlying cause. Primary SEP is idiopathic, and the etiology remains unclear. The primary SEP was reported to occur more commonly in tropical and subtropical countries. On the other hand,

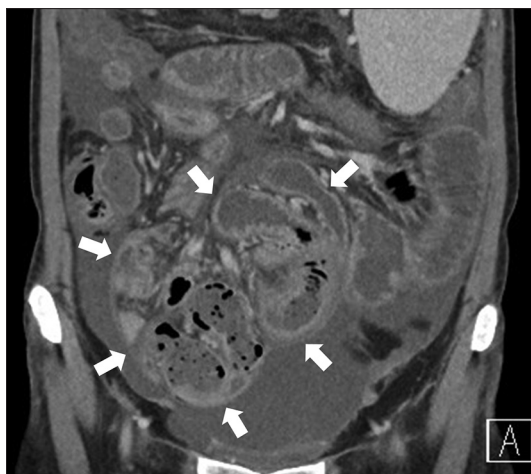


**Figure 1:** Abdominal X-ray (erect) shows no specific findings suggestive of intestinal obstruction



**Figure 2:** Axial computed tomography shows that the small intestinal loops are encased by the thick and sac-like membrane (white arrow). Dilatation of the small intestine and thickening of the intestinal wall are observed inside the sac

Kang: Sclerosing encapsulating peritonitis



**Figure 3:** Coronal computed tomography shows that dilated small intestinal loops containing air-fluid levels were enclosed in the sclerosing sac (white arrow) with small amounts of ascites

the secondary SEP is associated with several causes, but the most significant risk factor is PD. The incidence of SEP ranges from 0.14% to 2.5% in PD patients and increases with the duration of PD.<sup>[2,3]</sup> Other rare causes of secondary SEP include intraperitoneal infection, beta-blocker use, tumor with peritoneal seeding, organ transplantation, previous abdominal surgery, LC with PVS, endometriosis, and systemic inflammatory diseases. Pathophysiology of SEP is still unclear and is thought to occur when the peritoneal inflammatory response progresses in patients with a predisposing condition.<sup>[1-3]</sup>

Although the incidence of SEP is rare in LC patients who have never experienced PD, there are several case reports. Yamamoto *et al.*<sup>[4]</sup> reported two SEP cases in LC patients, who had never received PD or PVS. They suggested that persistent low-grade peritonitis, such as SBP, might be a risk factor for SEP in patients with LC. Furthermore, Caldwell and Dyer<sup>[5]</sup> reported a case of SEP caused by complication after splenectomy in LC patients with SBP. They suggested that abdominal surgery might be a mechanical irritation that triggered SEP development. In this case, there was no evidence that the patient has recently had SBP, so the direct causal relationship between LC and SEP is unclear. Furthermore, the patient had no history of causing a peritoneal violation other than laparoscopy a month ago. Therefore, the previous laparoscopy was presumed to be an inciting factor in the development of the patient's SEP.

The clinical presentation of SEP usually includes episodes of intermittent and partial intestinal obstruction. At the initial phase, most patients complain of nonspecific symptoms such as abdominal pain, nausea, and weight loss. There is no specific laboratory test to SEP, and abdominal X-ray findings have no diagnostic

specificity and only indicate features of intestinal obstruction. Therefore, the preoperative diagnosis of SEP is clinically difficult. Previous studies have reported that many cases have been diagnosed during laparotomy, adversely affecting the patient's prognosis. Many researchers emphasize that better awareness of the disease, careful clinical examination, and further radiologic evaluations are essential for preoperative diagnosis of SEP.<sup>[1-3,6,7]</sup> Recently, CT is recommended as the most reliable modality for preoperative diagnosis of SEP. CT findings of SEP are characterized by clustered small intestinal loops encased by sac-like dense fibrous membranes, small intestinal loops in the sac adhere to each other, and intestinal walls are thickened and dilated. Furthermore, additional CT findings may be accompanied: peritoneal or mesenteric thickening, intestinal wall or peritoneal calcification, localized fluid collections, and lymphadenopathy.<sup>[8,9]</sup> In this case, the patient's CT findings showed typical characteristics of SEP, which provided a decisive diagnostic clue for preoperative diagnosis in the ED.

Treatment of SEP should be adjusted to each patient depending on the extent and stage of the disease. In patients with minimal abdominal symptoms, conservative management with adequate nutritional support and proper treatment of underlying diseases are recommended as a first-line therapy, which is also effective in preventing subsequent surgical complications. In patients who do not respond to conservative treatment, immunosuppressants and antifibrotics should be considered. Of the immunosuppressants, corticosteroids are the best studied and mainly used. Corticosteroids inhibit collagen synthesis and maturation by suppressing the inflammatory process within the peritoneal membrane, thereby eliminating the thickened peritoneal membrane.<sup>[1-3]</sup> However, in patients with advanced peritoneal fibrosis, immunosuppressive therapy alone may not be effective, so combination therapy with antifibrotics is recommended. Tamoxifen is a selective estrogen receptor modulator with strong antifibrotic properties and has been reported to be effective for SEP by inhibiting the fibrosis process.<sup>[1-3,6]</sup> Surgical treatment of SEP is only recommended for patients with severe symptoms of intestinal obstruction, who do not respond to conservative and medical treatment. Surgical treatment is hazardous, technically difficult, and time-consuming. Moreover, not all surgeons are familiar with the required operative therapy.<sup>[1,2]</sup> In recent years, the surgical results have been improved by a better understanding of the disease and the accumulation of surgical experience. In a 17-year review of 239 cases in one center in Japan, in which mainly conducted enterolysis alone, mortality was 35.4%. Of which, death was related to SEP in 33 patients (18.2%), including 14 patients (7.7%) who died of postoperative

**Kang: Sclerosing encapsulating peritonitis**

complications.<sup>[10]</sup> In a study in one German institution that mainly performed peritonectomy and enterolysis, overall mortality was 10% at 1 year. Furthermore, the morbidity was 44%, which is better than previous reports.<sup>[11]</sup> In this case, the patient improved symptoms by conservative treatment without aggravating the symptoms that required surgical treatment.

### Conclusion

This case report illustrates the importance of differential diagnosis to benign causes of intestinal obstruction to obviate laparotomy. SEP is a rare disease, but emergency physicians should consider it as a differential diagnosis for patients with a history of peritoneal violations. Early diagnosis and proper treatment planning of SEP are important factors for the prognosis of patients. Abdominal CT is the most useful modality for the diagnosis of SEP in the ED. Emergency physicians should be aware of the disease entity of SEP and characteristic CT findings.

#### Ethical approval and consent to participate

The study was performed according to the Helsinki Declaration and approved by the Institutional Review Board of Jeju National University Hospital (IRB no. 2020-02-008). The requirement for informed consent was waived by the institutional review board. This manuscript is a simple case report with no risk to the patient and does not contain information to identify individual patients.

#### Author contribution statement

Jeong Ho Kang conceived and designed, and wrote the paper.

#### Funding

None.

#### Conflicts of interest

All authors declare that they have no conflicts of interest.

### References

1. Spence R, Gillespie S, Loughrey M, Gardiner K. Encapsulating peritoneal sclerosis – A 5 year experience. *Ulster Med J* 2013;82:11-5.
2. Danford CJ, Lin SC, Smith MP, Wolf JL. Encapsulating peritoneal sclerosis. *World J Gastroenterol* 2018;24:3101-11.
3. Machado NO. Sclerosing encapsulating peritonitis: Review. *Sultan Qaboos Univ Med J* 2016;16:e142-51.
4. Yamamoto S, Sato Y, Takeishi T, Kobayashi T, Hatakeyama K. Sclerosing encapsulating peritonitis in two patients with liver cirrhosis. *J Gastroenterol* 2004;39:172-5.
5. Caldwell J, Dyer A. Sclerosing encapsulating peritonitis (cocoon bowel) presenting after laparotomy for splenic abscess. *J Radiol Case Rep* 2013;7:17-23.
6. Akbulut S. Accurate definition and management of idiopathic sclerosing encapsulating peritonitis. *World J Gastroenterol* 2015;21:675-87.
7. Wei B, Wei HB, Guo WP, Zheng ZH, Huang Y, Hu BG, *et al.* Diagnosis and treatment of abdominal cocoon: A report of 24 cases. *Am J Surg* 2009;198:348-53.
8. George C, Al-Zwae K, Nair S, Cast JE. Computed tomography appearances of sclerosing encapsulating peritonitis. *Clin Radiol* 2007;62:732-7.
9. Stuart S, Stott D, Goode A, Cash CJ, Davenport A. Can radiological assessment of abdominal computerized scans diagnose encapsulating peritoneal sclerosis in long-term peritoneal dialysis patients? *Nephrol* 2017;22:19-24.
10. Kawanishi H, Shintaku S, Moriishi M, Dohi K, Tsuchiya S. Seventeen years' experience of surgical options for encapsulating peritoneal sclerosis. *Adv Perit Dial* 2011;27:53-8.
11. Ulmer C, Braun N, Rieber F, Latus J, Hirschburger S, Emmel J, *et al.* Efficacy and morbidity of surgical therapy in late-stage encapsulating peritoneal sclerosis. *Surgery* 2013;153:219-24.