



Case Report

Air embolism through open hub of external jugular vein intravenous cannula

Chitta R. Mohanty^a, Suma R. Ahmad^b, Mantu Jain^{c,*}, Bhavna Sriramka^d^a Department of Trauma & Emergency, AIIMS, Bhubaneswar, 751019, India^b Department of Anaesthesia and Critical Care, AIIMS, Bhubaneswar, 751019, India^c Department of Orthopaedics, AIIMS, Bhubaneswar, 751019, India^d Department of Anaesthesia and Critical Care, IMS & SUM Hospital, Bhubaneswar, 751003, India

ARTICLE INFO

Keywords:

Air embolism
External jugular vein
Intravenous cannula
Vigilance

ABSTRACT

Introduction: Venous air embolism is a catastrophic complication that can result in sudden cardiac arrest and death. Massive air embolism has been reported with central venous catheter through the internal jugular and subclavian veins. Though external jugular vein is a potential site of an air embolism to cardiac chambers and subsequently to vital organs such as brain, heart and lungs but has not been reported yet in literature.

Case presentation: We are reporting a case of sudden pulmonary air embolism in a patient through the open hub of an intravenous cannula, vigilant monitoring and timely action saved the patient from a catastrophic outcome.

Conclusion: We recommend vigilant monitoring and adequate precaution in patients with external jugular venous cannulation in the operation theater, intensive care unit or wards to prevent iatrogenic complications.

1. Introduction

External jugular venous (EJV) cannulation is being increasingly used in emergency patients for fluid and inotrope administration.¹ Air embolism is a catastrophic complication that can result in sudden cardiac arrest and death. Massive air embolism has been reported with central venous cannulation through the internal jugular and subclavian veins.^{2,3} Although the external jugular vein is a potential site of an air embolism to the cardiac chambers and subsequently to the lungs, in the literature, there is only one case report published.⁴ We are reporting a case of sudden pulmonary air embolism in a patient being operated for fracture humerus, through the open hub of an intravenous (IV) cannula in the EJV. However, vigilant monitoring and timely action averted a calamitous outcome.

2. Case presentation

A 48-year old male, BMI-27, ASA grade I, who sustained a bilateral proximal humerus fracture in a road traffic accident 5 days prior to hospital admission was posted for bilateral open reduction and internal fixation. His preoperative investigations were within normal limits, with a hemoglobin value of 14 g m%. The patient had a 16 Gauge IV cannula in the right EJV which was inserted in the emergency

department during initial resuscitation. Before induction of anesthesia, another 16 Gauge cannula was inserted in the right lower limb in anticipation of the additional blood loss during a bilateral surgery. The patient was administered general anesthesia and positioned in the beach chair position. Sterile draping covered the head end of patient and anesthetic machine was shifted back a little to enable two surgical teams to operate simultaneously. The surgery started uneventfully with all vitals in the normal range. An invasive arterial line was secured in the right dorsalis pedis artery for blood pressure (BP) monitoring. During surgery, the anesthetist noticed a sudden drop in end-tidal carbon dioxide (ETCO₂) to 26 mm Hg followed by a fall in the oxygen saturation (Fig-1 & Table-1). Immediately, the FiO₂ was raised to 100%, flow increased to 6 liter/min, and nitrous oxide (N₂O) was switched off. This was associated with tachycardia (heart rate-156/min), sudden hypotension (BP-50/30) and slight ST segment depression on the ECG. An arterial blood sample was taken from the arterial line for urgent arterial blood gas examination. The surgery was stopped and a search for the possible cause of intraoperative hemodynamic and respiratory changes was carried out. Meanwhile, injection adrenaline 100 µg IV and ringer lactate bolus was administered. The estimated blood loss was about 400 ml. We found the IV set detached from the EJV cannula and the internal jugular vein distended. The EJV cannula was promptly closed. On auscultation, no clinical murmur was heard

Peer review under responsibility of The Emergency Medicine Association of Turkey.

* Corresponding author.

E-mail address: montu_jn@yahoo.com (M. Jain).<https://doi.org/10.1016/j.tjem.2019.06.002>

Received 5 March 2019; Received in revised form 8 May 2019; Accepted 20 June 2019

Available online 26 June 2019

2452-2473/ 2019 Emergency Medicine Association of Turkey. Production and hosting by Elsevier B. V. on behalf of the Owner. This is an open access article under the CC BY-NC-ND license (<http://creativecommons.org/licenses/by-nc-nd/4.0/>).

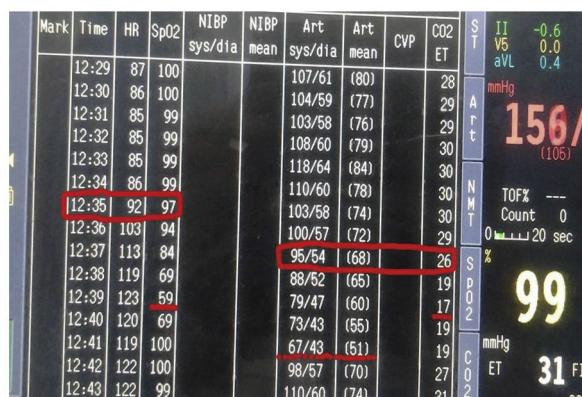


Fig. 1. Desaturation, drop in the ETCO₂ and hypotension within a span of 5 minutes depicted in the trend of vitals of the monitor.

Table 1
Trend of patient vitals as seen in the monitor.

Time	Heart Rate (HR) beats/min	Oxygen saturation (SPO ₂)	Invasive blood pressure (IBP) Systole/Diastole (Mean)	End-tidal carbon dioxide (ETCO ₂)
12:29 PM	87	100	107/61 (80)	28
12:30 PM	86	100	104/59 (77)	29
12:31 PM	85	99	103/58 (76)	29
12:32 PM	85	99	108/60 (79)	30
12:33 PM	85	99	118/64 (84)	30
12:34 PM	86	99	110/60 (78)	30
12:35 PM	92	97	103/58 (74)	30
12:36 PM	103	94	100/57 (72)	29
12:37 PM	113	84	95/54 (68)	26
12:38 PM	119	69	88/52 (65)	19
12:39 PM	123	59	79/47 (60)	17
12:40 PM	120	69	73/43 (55)	19
12:41 PM	119	100	67/43 (51)	19
12:42 PM	122	100	98/57 (70)	27
12:43 PM	122	99	110/64 (74)	31

over precordium and the chest was clear. We suspected pulmonary air embolism as a possible cause for the changes in ETCO₂, tachycardia and hypotension. The patient was placed in a Trendelenburg position with a left lateral tilt of the table, The ABG reports revealed a PH of 7.33, PaCO₂16 mm Hg, PaO₂ 60 mm Hg. In about 5 minutes, the patient responded. With return of ETCO₂ to baseline, restoration of oxygen saturation to 100%, improvement of BP to 112/64 mm Hg and reduction of HR to 122 beats/min. The rest part of surgery was completed uneventfully. Patient was extubated and sent to intensive care unit for observation with intact neurological function and stable vitals. The urine sample turned negative for fat globules. Next morning, the patient was shifted to the ward and continuously monitored for vitals, temperature and any neurological dysfunction. With all parameters in normal range, the patient was discharged on the fourth postoperative day having a with satisfactory check x-ray.

3. Discussion

Bilateral humerus fracture surgery poses a restricted area for IV cannulation and BP monitoring. Draping of the surgical part obscures the neck vein cannulation. As two teams were simultaneously operating, the anesthesia machine and the anesthetist moved away from the operating field. Surgeon's manipulation of the operative site may have caused the disconnection between the IV cannula and IV line without the anesthetist realizing this. Air entrainment can occur because of the gradient between the external atmospheric pressure and the

intravascular low venous pressure, which may be sub-atmospheric at baseline values in up to 40% of patients.⁵ This gradient can be increased by hypovolemia and patient position, which could be risk for air embolism in our case. Kapoor et al. have described the solitary case train of air bubbles in the EJV during neck dissection in a patient, which they were able to manage successfully.⁴ Else venous air embolism (VAE) has been reported more commonly during insertion or removal of central venous catheter by the interventionist with a rate up to 2% apart from the surgical procedure per se.⁶

Even though the many cases may be subclinical and dormant, VAE remains a medical emergency with reported fatality as high as 50–80%.⁷ Clinical manifestation of VAE depends on volume of air entrainment that manifest mainly as cardiovascular, respiratory, and central nervous system dysfunction.^{7,8} In an intubated patient, sudden decrease in the ETCO₂ level should alarm the anesthetist of altered ventilation - perfusion relation and possible obstruction of pulmonary arteries.⁸ Transesophageal echocardiography and precordial doppler ultrasonography are sensitive tools that can detect air of 0.02–0.05 ml/kg.^{9,10} In the absence of this facility in our trauma operation theatre, high clinical suspicion remains the mainstay in diagnosis.

Fat embolism (FE) is a very important differential diagnosis particularly in orthopedic scenario for intraoperative hypoxemia and hypotension.¹¹ FE is can occur in long-bone fractures and even during intramedullary nailing but is usually asymptomatic. Few patients do develop signs and symptoms of multiorgan dysfunction, particularly involving the triad of lungs, brain, and skin.¹² Massive intraoperative pulmonary FE, leading to fatal outcomes has been rarely reported in the literature.¹³ FE however was excluded in this case as the hypoxemia was easily reversed with positioning and stopping N₂O administration. Moreover, fever and petechiae were absent. The urine fat globules were also negative there was no neurological dysfunction post operatively.

4. Conclusion

Vigilant monitoring of patients having EJV cannulation for fluid and vasopressor therapy is of utmost importance in preventing complications such as VAE. Strong clinical suspicion in absence of intraoperative echocardiography forms the cornerstone in aggressively managing these morbid conditions.

Authors contribution

MJ was chief operating surgeon where CM was anesthetist. SA was help when the episode occurred. MJ and CR followed up patient while BS and SA reviewed the literature. SA, BS and MJ wrote up the paper. All authors have read and agree to content of manuscript.

Competing interest

None.

Source of funding

None.

Acknowledgement

We acknowledge the patient for permitting us to share this event for the benefit of medical practice.

References

- Prasad VSV, Daharwal S, Bahe A. External jugular venous access in children : a low cost and feasible route for emergency fluid resuscitation and inotropic therapy in resource poor clinical settings ? *J Pediatr Crit Care*. 2016;3(3):16–21.
- Vesely TM. Air embolism during insertion of central venous catheters. *J Vasc Interv*

- Radiol.* 2001;12:1291–1295.
3. Wong SS, Kwaan HC, Ing TS. Venous air embolism related to the use of central catheters revisited: with emphasis on dialysis catheters. *Clin Kidney J.* 2017;10(6):797–803.
 4. Kapoor D, Dhal A, Singh J, et al. “Anesthesia bubbles:” Demystifying the enigma!. *Saudi J Anaesth.* 2017;11:252–254.
 5. Puri VK, Carlson RW, Boner JJ, Weil MH. Complications of vascular catheterization in the critical ill. A prospective study. *Crit Care Med.* 1980;8:495–499.
 6. Phifer TJ, Bridges M, Conrad SA. The residual central venous catheter track- an occult source of lethal air embolism. *J Trauma.* 1991;31:1558–1560.
 7. Sheikh N, Ummunsia F. Acute management of vascular air embolism. *J Emergencies, Trauma, Shock.* 2009;2(3):180–185.
 8. Gordy S, Rowell S. Vascular air embolism. *Int J Crit Illn Inj Sci.* 2013;3(1):73–76.
 9. Jaffe RA, Siegel LC, Schnittger I, Propst JW, Brock-Utne JG. Epidural air injection associated with air embolism detected by transesophageal echocardiography. *Reg Anesth.* 1995;20:152–155.
 10. Soriano SG, McManus ML, Sullivan LJ, Scott RM, Rockoff MA. Doppler sensory placement during neurosurgical procedures for children in prone position. *J Neurosurg Anesthesiol.* 1994;6:153–155.
 11. Sheikh N. Emergency management of fat embolism syndrome. *J Emergencies, Trauma, Shock.* 2009;2(1):29–33.
 12. Kwiatt Michael E, Seamon Mark J. Fat embolism syndrome. *Int J Crit Illn Inj Sci.* 2013;3(1):64–68.
 13. Igarashi M, Kita A, Nishikawa K, et al. Use of percutaneous cardiopulmonary support in catastrophic massive pulmonary fat embolism. *Br. J. Anesth.* 2006;96(2):213–215.