



## Case Report

## Axillary artery laceration after anterior shoulder dislocation reduction

Yesim Eyler<sup>a,\*</sup>, Turgay Yılmaz Kilic<sup>a</sup>, Ali Turgut<sup>b</sup>, Onur Hakoglu<sup>a</sup>, Hasan Idil<sup>a</sup><sup>a</sup> Attending Physician of Emergency Medicine, Department of Emergency Medicine, Tepecik Training and Research Hospital, Izmir, Turkey<sup>b</sup> Attending Physician of Orthopedics and Traumatology, Department of Orthopedics and Traumatology, Tepecik Training and Research Hospital, Izmir, Turkey

## ARTICLE INFO

## Keywords:

Shoulder dislocation  
Axillary artery injury  
Reduction  
Emergency department

## ORCID

YE: 0000-0002-4024-7900  
TYK: 0000-0002-3494-5120  
AT: 0000-0002-0429-2165  
OH: 0000-0002-8039-0058  
HI: 0000-0001-5828-3224

## ABSTRACT

**Introduction:** Glenohumeral dislocation is the most commonly encountered dislocation in the emergency department. The most frequent complications of glenohumeral dislocation are rotator cuff tears and an increase in the risk of recurrent dislocation. Less common acute complications include fractures, neurological complications and vascular injuries. The incidence of axillary artery injury associated with shoulder dislocation is reported to be about 1–2%.

**Case:** An 81-year-old male presented to the emergency department with pain in the right shoulder after a fall. On physical examination, the shoulder was in slight abduction and external rotation. Shoulder movements were painful and there was a swelling in the axillary region which was tender to palpation. There was no sensory or motor deficit and the peripheral pulses were equal and palpable. Following the administration of analgesics, shoulder reduction was performed using the flexion-adduction-external rotation method. After reduction, the patient started complaining of axillary pain. On control examination, the patient did not have any motor or sensory deficits, but peripheral pulses were not palpable on the right arm. The right upper extremity computed tomography angiography, which was performed with the suspicion of vascular injury, revealed a right axillary artery rupture.

**Conclusion:** Axillary artery injury accompanying anterior shoulder dislocation is a rare but serious condition which may result in limb loss and death.

## 1. Introduction

Glenohumeral dislocation is the most commonly encountered dislocation in the emergency department and in most cases, the humeral head dislocates anteriorly.<sup>1,2</sup> The most frequent complications of glenohumeral dislocation are rotator cuff tears and an increase in the risk of recurrent dislocation. Less common acute complications include fractures, neurological complications and vascular injuries.<sup>3</sup> The incidence of axillary artery injury associated with shoulder dislocation is reported to be about 1–2%.<sup>4</sup> Axillary artery injury is more common in patients older than 40 years of age, and the severity of arterial injury varies between a simple intimal tear and a complete tear.<sup>5</sup>

Both dislocation and reduction may lead to arterial injury.<sup>6</sup> Because the clinical presentation of this rare vascular complication may be vague, the diagnosis often depends on high clinical suspicion, both before and after reduction. Axillary artery injury should be diagnosed and treated without delay, since it may lead to serious consequences such as limb loss and death. In this case report, we present a patient who suffered from axillary artery injury after the reduction of an

anterior shoulder dislocation.

## 2. Case Presentation

An 81-year-old male presented to the emergency department with pain in the right shoulder after a fall. His medical history was remarkable for hypertension, coronary artery disease, and recurrent dislocation of the right shoulder (4 times). His vital signs on arrival were as follows: blood pressure 133/101 mmHg, heart rate 118/min, respiratory rate 18/min, oxygen saturation 96%, body temperature 36,7 °C. On physical examination, the shoulder was in slight abduction and external rotation. Shoulder movements were painful and there was a swelling in the axillary region which was tender to palpation. There was no sensory or motor deficit and the peripheral pulses were equal and palpable.

After physical examination, right shoulder and chest x-ray images were obtained. A right anterior shoulder dislocation, which was not accompanied by a fracture, was detected in the right anteroposterior shoulder x-ray (Fig. 1A.). After informed consent was obtained for the

Peer review under responsibility of The Emergency Medicine Association of Turkey.

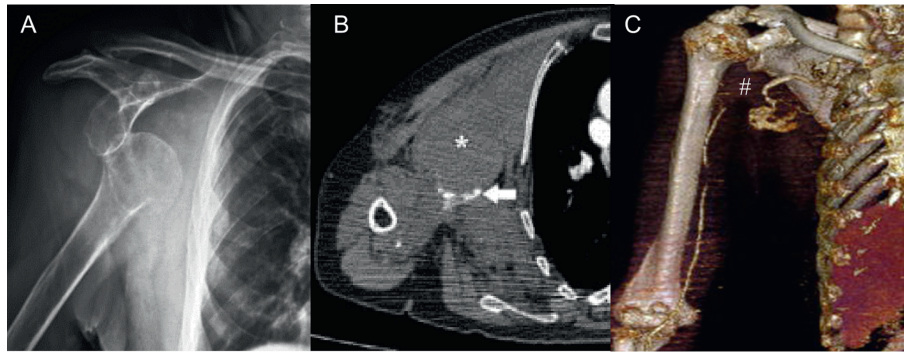
\* Corresponding author. Department of Emergency Medicine, Tepecik Training and Research Hospital, Gaziler Caddesi, Yenisehir, 35120, Izmir, Turkey.

E-mail address: [dryesimeyler@gmail.com](mailto:dryesimeyler@gmail.com) (Y. Eyler).<https://doi.org/10.1016/j.tjem.2018.10.004>

Received 9 October 2018; Accepted 31 October 2018

Available online 09 November 2018

2452-2473/ 2019 Emergency Medicine Association of Turkey. Production and hosting by Elsevier B. V. on behalf of the Owner. This is an open access article under the CC BY-NC-ND license (<http://creativecommons.org/licenses/by-nc-nd/4.0/>).



**Fig. 1.** A) X-ray revealing right anterior shoulder dislocation. B) Axial computed tomography angiography revealing large haematoma (asterisk), and contrast extravasation (arrow). C) 3D CT Angiography revealing rupture of the axillary artery (number sign icon).

reduction procedure, the patient was placed in supine position. Following the administration of analgesics, shoulder reduction was performed using the flexion-adduction-external rotation method. Since the patient had a history of recurrent shoulder dislocation, the reduction was performed easily, and the pain resolved soon after reduction. However, after a short while, the patient started complaining of axillary pain. On control examination, the patient did not have any motor or sensory deficits, but peripheral pulses were not palpable on the right arm and the swelling in the axillary region had increased in size. The right upper extremity computed tomography angiography, which was performed with the suspicion of vascular injury, revealed a right axillary artery rupture (Fig. 1B–C). The patient was transferred to the operating room for emergent surgery. A complete axillary artery rupture was observed during surgical exploration. The rupture was repaired and it was confirmed that there was no thrombus and that the arterial flow was adequate. After the operation, there were no motor or sensory deficits in the right arm and peripheral pulses were palpable. After being followed up in the intensive care unit for one day and in the ward for 3 days, the patient was discharged without complications. On the outpatient follow up visits, which were performed 2 times with 2-week intervals, no pathological findings were observed.

### 3. Discussion

Axillary artery injury is a rare complication of anterior shoulder dislocation, and an incomplete arterial rupture may easily be missed.<sup>7</sup> Early detection and treatment are crucial to prevent serious consequences of arterial injury, and this depends on combining a high index of suspicion with appropriate diagnostic algorithms.<sup>8</sup> Because of its anatomic position, axillary artery is prone to injury following a shoulder dislocation. The third part of the artery, which is distal to the pectoralis minor muscle, is the site most commonly injured.<sup>9</sup> In the literature, many theories have been proposed to explain the mechanism of injury.

The sudden kinking of the axillary artery over the edge of the pectoralis minor muscle, the tearing forces exerted on the artery by surrounding fibrotic adhesions, and the decreased elasticity of the atherosclerotic artery making it more susceptible to injury in case of shoulder dislocation, are other proposed theories.<sup>10</sup> Most of these injuries occur in advanced age due to the decreased elasticity of the atherosclerotic artery.<sup>7</sup> As a matter of fact, 90% of cases are above the age of 50 years.<sup>11</sup> Patients with axillary artery injury may present with the pathognomonic triad of shoulder dislocation, absence of ipsilateral peripheral pulses and expanding axillary haematoma. On the other hand, some patients may have none of these findings or these findings may develop gradually.<sup>8</sup> Intact pulses do not exclude arterial injury because the collateral arteries in the upper extremity may cause the

peripheral pulses to be palpable.

About one-third of the patients with axillary injury following shoulder dislocation have a history of recurrent dislocation.<sup>12</sup> The scar tissue caused by recurrent dislocations may lead to arterial compression, and render the artery more susceptible to injury during a future dislocation.<sup>8</sup> According to the literature, vascular injury is most likely to occur in an elderly patient with a history of recurrent shoulder dislocation, as in our case.<sup>5</sup>

Early diagnosis is crucial in patients with axillary artery injury.<sup>13</sup> A delay in treatment is the main cause of an unfavorable outcome. Doppler ultrasonography is a fast and noninvasive diagnostic method in patients with absent peripheral pulses and/or axillary swelling following shoulder dislocation or closed reduction, but it is operator-dependent.<sup>8</sup> Currently, CT angiography is the preferred diagnostic imaging modality in terms of showing the exact location of the injury and aiding with surgical planning.<sup>14</sup>

There are various options in the treatment of arterial injuries related to extremity traumas. The method of vascular repair differs depending on the extent and site of the injury. Most authors agree on the fact that the method of vascular repair should be determined intraoperatively, after visualizing the lesion with surgical exploration. Vascular repair methods include thrombectomy, end-to-end anastomosis, saphenous vein graft or prosthetic allograft with ligation of avulsed collaterals.<sup>15</sup>

### 4. Conclusion

Axillary artery injury accompanying anterior shoulder dislocation is a rare but serious condition which may result in limb loss and death. For this reason, physicians should be vigilant against vascular injury both before and after closed reduction, especially in older patients with a history of recurrent shoulder dislocation.

### References

- Zacchilli MA, Owens BD. Epidemiology of shoulder dislocations presenting to emergency departments in the United States. *J Bone Joint Surg Am.* 2010;92(3):542–549.
- Tas M, Canbora MK, Köse O, Egerci OF, Gem M. Demographic and clinical characteristics of traumatic shoulder dislocations in an urban city of Turkey: a retrospective analysis of 208 cases. *Acta Orthop Traumatol Turcica.* 2013;47(3):147–152.
- Perron AD, Ingerski MS, Brady WJ, Erling BF, Ullman EA. Acute complications associated with shoulder dislocation at an academic emergency department. *J Emerg Med.* 2003;24(2):141–145.
- Cutts S, Premphe M, Drew S. Anterior shoulder dislocation. *Ann R Coll Surg Engl.* 2009;91(1):2–7.
- Stayner L, Cummings J, Anderson J, Jobe C. Shoulder dislocation in patients older than 40 years of age. *Orthop Clin N Am.* 2000;31(2):231–239.
- Drury JK, Scullion JE. Vascular complications of anterior dislocation of the shoulder. *Br J Surg.* 1980;67(8):579–581.
- Kelley S, Hinsche A, Hossain J. Axillary artery transection following anterior shoulder dislocation: classical presentation and current concepts. *Injury.*

- 2004;35(11):1128–1132.
8. Bravman JT, Ipaktchi K, Biffi WL, Stahel PF. Vascular injuries after minor blunt upper extremity trauma: pitfalls in the recognition and diagnosis of potential “near miss” injuries. *Scand J Trauma Resuscitation Emerg Med.* 2008;16:16.
  9. Chehata Ash, HamishMorganb F, Bonato Luke. Axillary artery injury after an anterior shoulder fracture dislocation and “periosteal sleeve avulsion of the rotator cuff” (SARC). Case report and review of the literature. *Trauma Case Rep.* 2017;8:5–10.
  10. Allie B, Kilroy DA, Riding G, Summers C. Rupture of axillary artery and neuropraxis as complications of recurrent traumatic shoulder dislocation: case report. *Eur J Emerg Med.* 2005;12(3):121–122.
  11. Clayton DB, Ratzlaff RA. Axillary artery laceration after an anterior shoulder dislocation presenting as hypovolemic shock. *Am J Emerg Med.* 2016;34(8) 1739.e1-4.
  12. Lee WW. Axillary artery pseudoaneurysm and axillary nerve palsy: delayed sequelae of anterior shoulder dislocation. *Am J Emerg Med.* 1996;14(1):108–110.
  13. Oc M, Güvener M, Ucar HI, Akbulut B, Yilmaz M, Ersoy U. Isolated axillary artery injury due to blunt trauma. *Ulus Travma Acil Cerrahi Derg.* 2007;13(2):145–148.
  14. Peng PD, Spain DA, Tataria M, Hellinger JC, Rubin GD, Brundage SI. CT angiography effectively evaluates extremity vascular trauma. *Am Surg.* 2008;74(2):103–107.
  15. Sparks SR, DeLaRosa J, Bergan JJ, Hoyt DB, Owens EL. Arterial injury in uncomplicated upper extremity dislocations. *Ann Vasc Surg.* 2000;14(2):110–113.