



Case Report

Electrocardiographic changes in right ventricular metastatic cardiac tumor mimicking acute ST elevation myocardial infarction: A case of misdiagnosis

Vahit Demir ^{a,*}, Yasar Turan ^a, Hüseyin Ede ^a, Siho Hidayet ^a, Mustafa F. Erkoç ^b

^a Department of Cardiology, Medical Faculty of Bozok University, Adnan Menderes Bulvarı No:44, 66020, Yozgat, Turkey

^b Department of Radiology, Medical Faculty of Bozok University, Adnan Menderes Bulvarı No:44, 66020, Yozgat, Turkey

ARTICLE INFO

Article history:

Received 12 June 2018

Received in revised form

10 July 2018

Accepted 11 July 2018

Available online 17 July 2018

ORCID:

VD: 0000-0001-8349-6651

YT: 0000-0002-2796-899X

HE: 0000-0003-1218-257X

SH: 0000-0002-4103-9345

MFE: 0000-0002-6266-5177

ABSTRACT

Introduction: In patients with ST elevation myocardial infarction (STEMI), minimizing the reperfusion time is the goal of therapy worldwide. However, the differential diagnosis is critical and when a patient is encountered with chest pain and ST elevation, STEMI should not be the only diagnosis considered. By detailed history and focused physical examination, it is possible to avoid a mistaken diagnosis.

Case presentation: In this report, we present a case of a male patient with tongue cancer and accompanying myocardial metastasis that causes electrocardiographic changes, who was initially misdiagnosed with ST elevation myocardial infarction.

Conclusion: Here, we reported a case of metastatic cancer in the heart which was initially diagnosed as acute myocardial infarction. Echocardiography, computed tomography and magnetic resonance imaging of the heart were used accordingly to confirm the myocardial metastasis.

Copyright © 2019 The Emergency Medicine Association of Turkey. Production and hosting by Elsevier B.V. on behalf of the Owner. This is an open access article under the CC BY-NC-ND license (<http://creativecommons.org/licenses/by-nc-nd/4.0/>).

1. Introduction

Atherosclerosis leading to coronary occlusion is the most common reason for the development of ST elevation myocardial infarction (STEMI). Early coronary reperfusion is necessary in STEMI, because the beneficial effects of therapy with reperfusion are greatest when performed quickly. A variety of cardiac and noncardiac conditions have been known to mimic the electrocardiography (ECG) changes similar to those seen in STEMI. Noncardiac conditions mimicking STEMI are central nervous system disease, perforated duodenal ulcer, esophageal rupture, acute pancreatitis, pneumothorax, pneumomediastinum, hyperkalemia, hypocalcemia, hypercalcemia, pheochromocytoma, acute cor pulmonale, and normal variants. Cardiac conditions with ECG changes mimicking STEMI were described in early repolarization,

pericarditis, myocarditis, hypertrophic cardiomyopathy, Brugada syndrome, Takotsubo cardiomyopathy (broken-heart syndrome), and also in patients with left ventricular hypertrophy, left bundle-branch block.¹ However, the reported mimicking STEMI in association with cardiac tumors are in a few cases. Primary cardiac tumors are very rare compared to metastatic cardiac tumors. Nevertheless, the antemortem diagnosis of cardiac metastases is rarely made, because most of it, they are clinically silent.²

In this case report, a patient under treatment of tongue cancer presented with ECG changes mimicking acute anterior STEMI was described.

2. Case report

A 59-year-old man patient was brought to emergency service because of having acute onset of chest pain. He had a the tongue cancer diagnosed two years ago. Complete resection of the tumor was achieved, and radiotherapy is applied following the operation. There's been no symptoms for about three years. He had no history of major systemic disease such as diabetes mellitus, hypertension or cardiovascular diseases. On examination, he was in no distress; the blood pressure was 130/75 mmHg, the pulse rate 75 beats/min,

* Corresponding author.

E-mail addresses: vahit.demir@bozok.edu.tr (V. Demir), yasar044@hotmail.com (Y. Turan), huseyinede@gmail.com (H. Ede), shhidayet@hotmail.com (S. Hidayet), drerkoc@gmail.com (M.F. Erkoç).

Peer review under responsibility of The Emergency Medicine Association of Turkey.

respiratory rate 18 breaths/min and body temperature of 36.7 °C, and oxygen saturation of 94%. The heart sounds were normal, and chest examination did not reveal any abnormalities. Repeat surface 12-lead ECG demonstrated sinus rhythm with evidence of ST-segment elevation in the all over the anterior leads (V1 to V6) which were compatible with acute anterior wall myocardial infarction (Fig. 1). The patient underwent immediate coronary angiography, which revealed non-critical stenosis coronary artery was detected. Chest X-ray showed clear pulmonary examination with a mildly-dilated heart. Standard transthoracic echocardiography (TTE) revealed a giant tumor involving free wall of the right ventricular (RV) and filling the cavity. Additionally, echocardiography also revealed RV wall hypokinesia involving the mid to apex and indicating the tumoral invasion (Fig. 2-A). The short-axis view of TTE showed a D-shaped left ventricle. Computed tomography with contrast (CT) and magnetic resonance imaging (MRI) were performed to get detailed information about the mass. Finally, a tumor in the RV was confirmed (Fig. 2-B). The ST elevations on the ECG remained static and serial cardiac troponin measurements were repeatedly negative. We suspected the tumor to be a metastasis secondary to primary tongue cancer based on its echocardiographical features and the patient's past history. Referral to the oncology department was ordered. During the follow-up, sepsis was developed and the patient died two months after metastatic cardiac cancer was detected.

3. Discussion

We reported a case of tongue cancer with myocardial involvement, with ECG changes mimicking acute myocardial infarction. Before the echocardiography was in use, only sporadic case reports diagnosed in the right-sided cardiac tumors by angiography and received surgical excision. Echocardiography is the mainstay of diagnosis nowadays. However, the echocardiography diagnosis of a tumor within the heart is not always straightforward.³ Differential diagnosis that should be considered, apart from metastasis, includes primary cardiac tumor -primarily myxoma, vegetation, or thrombus. Considering the location of the mass along with echogenicity and combining all these data with medical history of the

patient often result in an accurate diagnosis. Most physicians consider transesophageal echocardiography by the method of choice for optimal visualisation of heart morphology. Transesophageal echocardiography was not performed in our patient because of swallowing difficulty and neck radiotherapy story. Other modalities, including CT and MRI, can help in delineating the exact location and extent of extracardiac extension and to demonstrate the effects of the lesion on surrounding structures.⁴ Thoracic CT helped to detect myocardial involvement of the cancer that was not noticed before. Echocardiography, MRI, and CT are useful diagnostic tools to assess neoplastic infiltration to the myocardium. There is still there is no clear-cut advice on the treatment of cardiac metastasis. The operative mortality rate of such patients is extremely high.^{2,5} Due to their rarity and poor outcome, cardiac metastases represent a challenging clinical problem. Individualized treatment plans should be implemented in a multidisciplinary approach considering the functional capacity, tumor characteristics and previous treatment. Although the surgery seems to be the best option at the moment.⁶ The prognosis of cardiac metastasis is poor with an average life expectancy less than six months after diagnosis.⁷ In our case, ECG showed characteristic abnormality. The exact cause of this ECG abnormality is unknown, but myocardial injury of the RV apex wall attributed to the metastatic tumor may have resulted in the ECG abnormality. In the same way, neoplastic process can be due to metastasis, tumor invasion into the myocardium, tumor emboli within a coronary artery, or a metastatic lesion surrounding a coronary artery. This patient did not have characteristic enzyme and ECG evolution for acute myocardial infarction. The ST segment elevation was due to a metastatic tumor that invaded the pericardium and myocardium. Suggested mechanisms for these pseudo-infarction ECG patterns are continuous myocardial injury preventing formation of new cardiac cell membrane, stretched adjacent muscle fibers, inflammatory reaction, the ionic transfer of potassium from necrotic tissue to the adjacent myocardium, and transfer of potassium from damaged tissue to the adjacent myocardium producing electropotential differences.⁸ A similar cardiac metastasis of bladder cancer, which ECG abnormality was reported by Na et al. in a case of mimicking ST-segment elevation in myocardial infarction.⁹ In another case, Nakashima

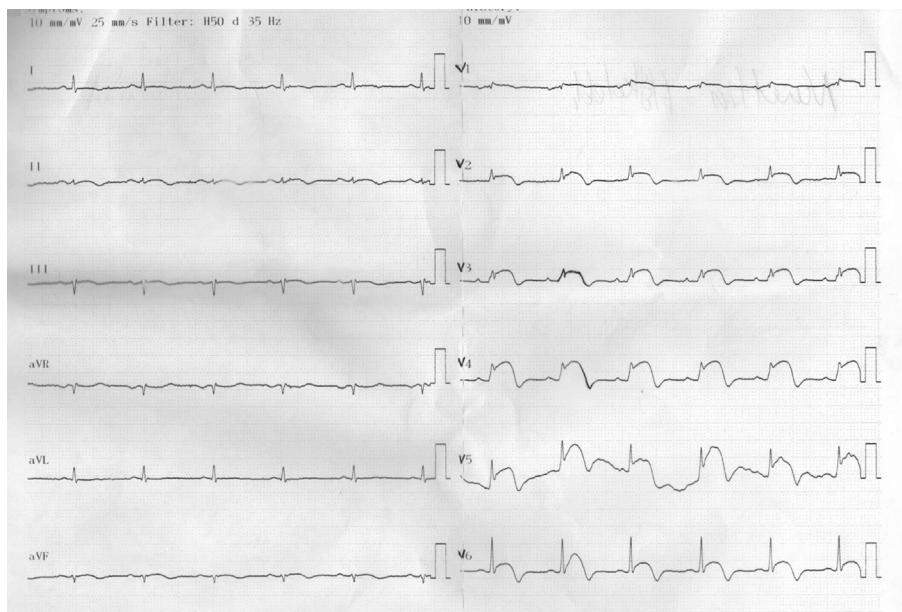


Fig. 1. ECG demonstrated normal sinus rhythm, permanent marked S-T segment elevation, biphasic inversion of T-waves in leads V1-V6 and the absence of a Q wave.

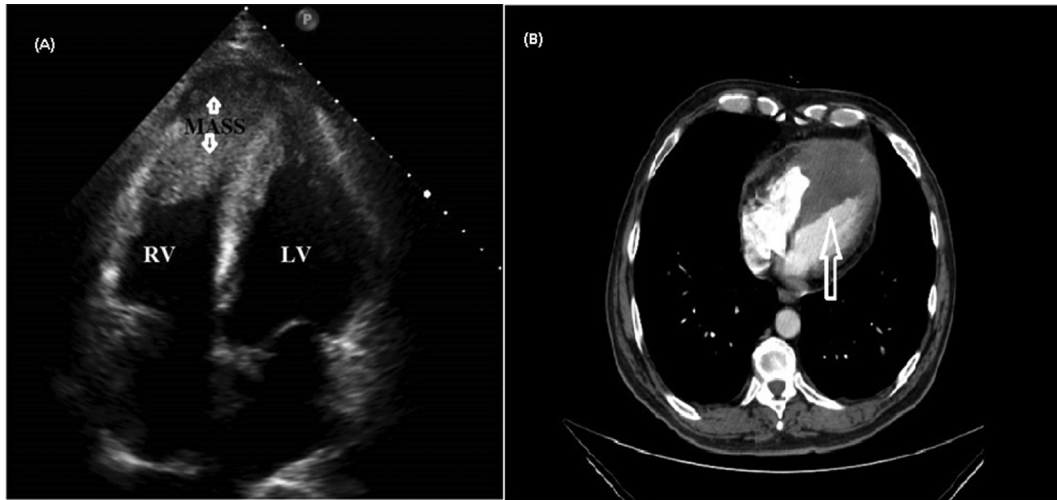


Fig. 2. (A)The apical 4-chamber plane showed a RV mass that was 45 × 32 cm in size (arrows). (B) Contrast-enhanced CT scans (axial view). Mass was found in the right ventricular chamber.

et al. reported ECG showed characteristic abnormality (ST segment elevation and T inversion in leads V1-V6) with metastatic cardiac tumor from urothelial carcinoma.¹⁰ Detailed history, physical examination, basic laboratory tests, or imaging studies can generally exclude acute myocardial infarction in such cases.¹¹ Unnecessary invasive procedures can thus be avoided.

4. Conclusion

Here, we reported a case of metastatic cancer in the heart which was initially diagnosed as acute myocardial infarction. Metastatic myocardial infiltration due to the tumor should be suspected when ECG changes without typical angina are found in a patient with malignancy and negative cardiac enzymes in the blood.

Declaration interest

The authors declare that they have no competing interest.

Grant support & financial disclosures

None.

Acknowledgement

Some part of the case was presented as a poster in 14th International Congress of Update In Cardiology and Cardiovascular

Surgery held in Antalya, Turkey and the abstract of the case report in the proceeding book of the congress was published in *Am J Cardiol.* 2018;121(8):e130 accordingly.

References

1. Yahalom M, Roguin N, Suleiman K, Turgeman Y. Clinical significance of conditions presenting with ECG changes mimicking acute myocardial infarction. *Int J Angiol.* 2013;22(2), 115–22.
2. Al-Mamgani A, Baartman L, Baaijens M, De Pree I, Incrocci L, Levendag PC. Cardiac metastases. *Int J Clin Oncol.* 2008;13, 369–72.
3. Peters PJ, Reinhardt S. The echocardiographic evaluation of intracardiac masses: a review. *J Am Soc Echocardiogr.* 2006;19:230–240.
4. Chieng SH, Lin CH, Lu MJ, Hung CR. Intracavitary metastatic hepatocellular carcinoma of the right ventricle. *Thorac Cardiovasc Surg.* 2005;53:123–125.
5. Kato Y, Tanaka N, Kobayashi K, Ikeda T, Hattori N, Nonomura A. Growth of hepatocellular carcinoma into the right atrium: a report of five cases. *Ann Intern Med.* 1983;99:472–474.
6. Unusual case of spindle cell sarcoma metastases to right ventricle. A case report and a literature review. *Ann Transl Med.* 2017;5(17):344.
7. Okamoto K, Kusumoto T, Seki N, Nakamura K, Hiramatsu Y. A case of cardiac metastasis from uterine cervical cancer. *Case Rep Obstet Gynecol.* 2015, 703424.
8. Pan KL, Wu LS, Chung CM, Chang ST, Lin PC, Hsu JT. Misdiagnosis: cardiac metastasis presented as a pseudo-infarction on electrocardiography. *Int Heart J.* 2007;48(3):399–405.
9. Na JO, Choi CU, Lim HE. Cardiac metastasis of bladder cancer presented as mimicking ST segment elevation myocardial infarction. *Eur Heart J.* 2011;32:40.
10. Nakashima Y, Tanioka K, Kubo T, et al. Metastatic cardiac tumor from urothelial carcinoma detected by transthoracic echocardiography: a case report. *J Med Case Rep.* 2015:257.
11. Demir V, Ede H, Sahin S, Akgun O, Turan Y, Erbay AR. A case of atypically located left atrial myxoma with concomitant acute myocardial infarction and severe pulmonary hypertension. *Int J Cardiovasc Acad.* 2016;2(3):143–146.