

## Case Report

## Isolated vocal cord hematoma developing after blunt neck trauma

Ceyhun Aksakal<sup>a,\*</sup>, İlgit Karaca<sup>b</sup><sup>a</sup> Ear Nose Throat Department, Tokat State Hospital, Tokat, Turkey. ORCID: 0000-0001-9770-1513<sup>b</sup> Emergency Department, Tokat State Hospital, Tokat, Turkey. ORCID: 0000-0003-1656-2481

## A B S T R A C T

**Introduction:** Blunt laryngeal trauma is a rare causes of emergency applications.

Early diagnosis and treatment are important.

**Case presentations:** A 62-year-old woman applied to emergency department with pain over the larynx, hoarseness and dysphagia that starting after blunt laryngeal trauma. The patient had no respiratory distress. There was no ecchymosis and edema in the laryngeal area. Computed tomography showed no thyroid and cricoid cartilage fractures. Isolated hematoma was seen in the left vocal cord at the endoscopic view.**Conclusion:** Endoscopic examination is important when there is no obvious physical examination finding on the in blunt neck trauma.

## 1. Introduction

Blunt laryngeal trauma is the trauma that can cause clinically significant and life-threatening complications.<sup>1</sup> The most common causes of blunt laryngeal traumas are motorcycle accidents, fight and sports accidents. Following the blunt laryngeal trauma; the situations ranging from the neck laceration and laryngeal mild edema to laryngotracheal separation resulting in death and the life-threatening airway obstruction, may occur according to the severity of the trauma.<sup>2</sup> Following blunt laryngeal trauma, the most common symptoms during emergency department (ED) admissions are pain over the larynx and hoarseness. In addition, the situations such as loss of consciousness, stridor, participation of chest muscles to breathing can be seen depending on the severity of trauma in cases. In this respect, blunt laryngeal trauma is important in terms of the urgency of diagnosis and treatment. In this case report, we presented a female patient with isolated vocal cord and arytenoid hematoma developed following blunt laryngeal trauma.

## 2. Case presentation

A 62-year-old woman admitted to ED complaints of pain over the larynx, sudden onset of hoarseness and dysphagia. In her anamnesis, it was learnt that the patient hit her neck to a stiff ware after the falling, when she was putting ware to high place at home. In the medical history of the patient, there was no laryngeal disease and hoarseness. Oxygen saturation was 98%. There was no asymmetry, crepitation, ecchymosis, edema, laceration over the larynx. There was no pathological finding in the physical examination. In the neck computed

tomography (CT) was performed on the patient. In CT, it was seen that the laryngotracheal integrity was complete and there is no finding of fracture in the thyroid and cricoid cartilage. In the left vocal cord and left arytenoid region increase in mucosal thickness was observed (Fig. 1). In the flexible fiberoptic endoscopic examination; it was seen that there was a localized hematoma in left vocal cord and left arytenoid (Fig. 2). Vocal cords movements were was normal.

The dexamethasone at 8 mg dose was intravenously given to the patient at every 8 hours for 24-h and cold steam were administered. After 24 hours of follow-up in clinic, he was discharged. 7 days of antibiotic therapy and proton pump inhibitor therapy were given. At 1st week, even though there was a decrease in the hoarseness complaint of the patient. At the control of 1st month, hoarseness and dysphagia were totally recovered, and the it was seen that hematoma of the vocal cord completely regressed at the endoscopic examination.

## 3. Discussion

The patient with a laryngeal trauma may admit to ED due to complaints ranging from the hoarseness to the life-threatening airway obstruction findings. However, respiratory distress symptoms may develop during the progressive stages in the patients admitted with hoarseness. In this respect, careful laryngeal examination is important in patients admitted with blunt laryngeal trauma.<sup>3</sup> In blunt laryngeal trauma, it is important to investigate the findings such as the edema and ecchymosis in neck, and detection of the crepitation and asymmetry in laryngeal examination. In our patient, hoarseness and pain over the larynx were the prominent symptoms.

Peer review under responsibility of The Emergency Medicine Association of Turkey.

\* Corresponding author. Tokat State Hospital Ear Nose Throat Department, 60100, Tokat, Turkey.

E-mail address: [aksakalceyhun@gmail.com](mailto:aksakalceyhun@gmail.com) (C. Aksakal).<https://doi.org/10.1016/j.tjem.2018.08.004>

Received 8 July 2018; Received in revised form 27 August 2018; Accepted 31 August 2018

Available online 06 September 2018

2452-2473/2019 Emergency Medicine Association of Turkey. Production and hosting by Elsevier B. V. on behalf of the Owner. This is an open access article under the CC BY-NC-ND license (<http://creativecommons.org/licenses/by-nc-nd/4.0/>).

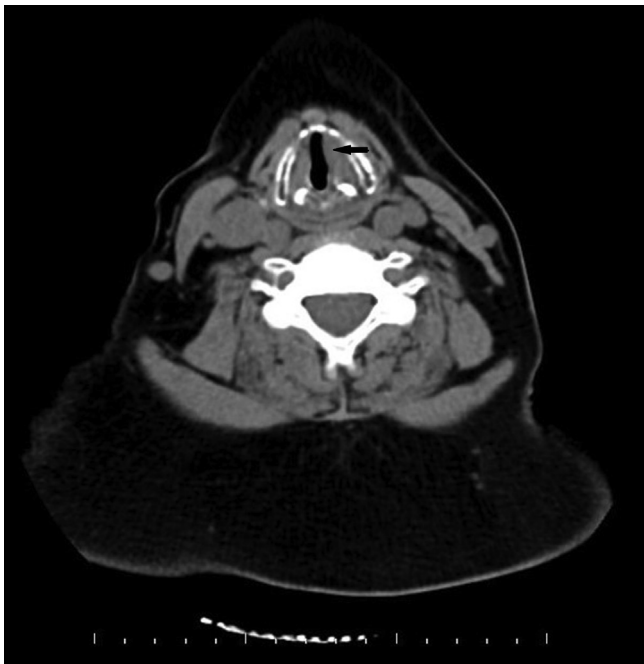


Fig. 1. Axial CT showed thickness around left vocal cord. (Black arrow).

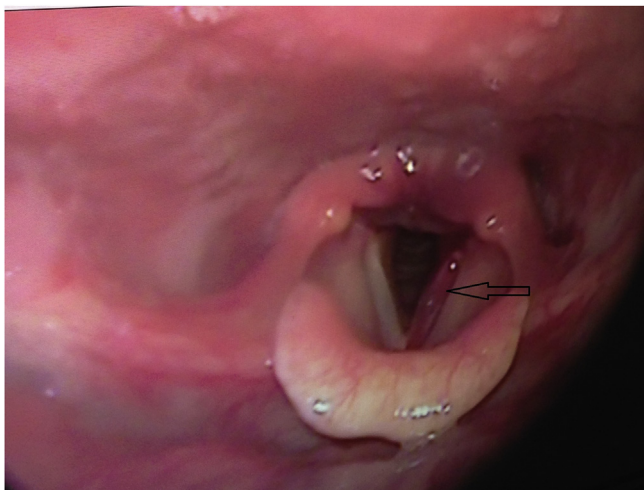


Fig. 2. Endoscopic view of left vocal cord hematoma. (Arrow: Left vocal cord hematoma.)

Schaefer proposed an algorithm in the patient with larynx trauma. According to this, in patients with blunt neck trauma and suspected laryngeal trauma, intubation or tracheotomy should be performed on patients if there is airway obstruction. After the airway is secured, the laryngeal examination should be done by direct laryngoscopy. If the airway is stable, the patient should be assessed by flexible fiberoptic laryngoscopy. If laryngeal fracture findings are present, the patient should be prepared for the operation. Airway stabilization should be evaluated by flexible fiberoptic laryngoscopy. Follow-up is recommended if findings of reversible mucosal trauma is present. However, if there is cartilage disruption, the patient should be prepared for the operation.<sup>4</sup>

CT is the most valuable diagnostic method in assessment of the laryngeal cartilages integrity and especially the airway.<sup>5</sup> In the CT of our patient, hematoma findings were present in the left vocal cord and arytenoid mucosa of the larynx. Even there is no evidence of airway obstruction in our patient, CT is recommended in all patients with blunt laryngeal trauma.<sup>3</sup> Another important tool in diagnosis is indirect

laryngoscopic evaluation. It is the most valuable diagnostic tool for the evaluation of the edema and possible hematoma in the larynx. Observation is recommended in indirect laryngoscopic evaluation in which the mucosal edema, vocal cord hematomas that do not threaten the airway, and small lacerations are seen.<sup>6</sup> In laryngoscopic evaluation of the our patient, hematoma was observed in the left vocal cord and arytenoid cartilage but this was not in a size to threaten the airway. Laryngeal trauma is divided into four groups by Schaefer. Group 1 consists of patients with minor endolaryngeal hematoma and laceration. The second group consisted of patients with massive endolaryngeal edema but without cartilage fracture, group 3 of patients with massive endolaryngeal edema, cord immobilization, cartilage fracture, and group 4 of patients with two or more cartilage fracture and another organ injury.<sup>6</sup> Emergency physician play a critical role in the early diagnosis, management and treatment of patients with laryngeal trauma. In these patients, late diagnosis can lead to disorders in the patient's airways and temporary and permanent disorders of the voice.<sup>7</sup> Late diagnosis of fractures in laryngeal cartilage may be caused by stenosis in the glottic, subglottic, and tracheal regions. At this point, the trauma mechanism of the patient is important. For example, while a hyoid fracture can be seen in the condition with hanging, the hitting of an object coming from the distant can cause a fracture in the laryngeal cartilage.<sup>2,8</sup>

The treatment of patients with blunt laryngeal trauma varies according to the severity of the trauma and the symptoms caused by trauma. It is recommended to apply some medical treatments during observation in patients with no airway obstruction. These include intravenous corticosteroids, antibiotics and proton pump inhibitors. The 8–10 mg of dexamethasone administration at every 8 hours for 24-h process is recommended. This treatment is very effective in reducing airway edema.<sup>9</sup> Although our patient does not have mucosal open wound, antibiotherapy is recommended as a prophylactic treatment in patients with laryngeal trauma. Proton pump inhibitors are recommended as the most important treatment against the scar caused by silent reflux.<sup>6,7,10</sup> In addition, cool humidified air, head elevation, voice rest are also recommended as additional treatment modalities in patients with endolaryngeal localized hematoma.<sup>1</sup>

Emergency physicians play an important role in determining the degree of airway intervention in patients with laryngeal trauma. Conditions such as airway collapse, severe edema require immediate intubation. In patients with dysphagia and hoarseness as in our patient, other treatments should be started after it is known that the airway is secured. After the airway is stabilized, treatment approaches of the emergency physician are important to prevent laryngeal complications that may develop in the long term.<sup>9</sup>

#### 4. Conclusion

In patients presenting with blunt laryngeal trauma detailed physical examination, CT and indirect laryngoscopy are the cornerstones of patient evaluation.

#### Funding

No Funding.

#### Author contribution statement

Ceyhun Aksakal 1,2,3,4,5.  
Ilgit Karaca 1,2,3,4.

#### Conflict of interest statement

The authors declare no conflict of interest.

## References

1. Moonsamy P, Sachdeva UM, Morse CR. Management of laryngotracheal trauma. *Ann Cardiothorac Surg*. 2018;7(2):210–216.
2. Leopold DA. Laryngeal trauma. A historical comparison of treatment methods. *Arch Otolaryngol*. 1983;109:106.
3. Shires CB, Preston T, Thompson J. Pediatric laryngeal trauma: a case series at a tertiary children's hospital. *Int J Pediatr Otorhinolaryngol*. 2011;75:401–408.
4. Schaefer SD. Management of acute blunt and penetrating external laryngeal trauma. *Laryngoscope*. 2014;124:233–244.
5. Becker M, Leuchter I, Platon A, et al. Imaging of laryngeal trauma. *Eur J Radiol*. 2014;83:142–154.
6. Schaefer SD. Primary management of laryngeal trauma. *Ann Otol Rhinol Laryngol*. 1982;91:399–402.
7. Butler AP, Wood BP, O'Rourke AK, et al. Acute external laryngeal trauma: experience with 112 patients. *Ann Otol Rhinol Laryngol*. 2005;114:361–368.
8. Yen PT, Lee HY, Tsai MH, et al. Clinical analysis of external laryngeal trauma. *J Laryngol Otol*. 1994;108:221–225.
9. Comer BT, Gal TJ. Recognition and management of the spectrum of acute laryngeal trauma. *J Emerg Med*. 2012;43:289–293.
10. Kantas I, Balatsouras DG, Kamargianis N, et al. The influence of laryngopharyngeal reflux in the healing of laryngeal trauma. *Eur Arch Oto-Rhino-Laryngol*. 2008;266:253–259.