



Case Report

A rare case of an adult traumatic bicycle handlebar hernia: A case report and review of the literature

Ashraf F. Hefny^{a, *}, Jagalpathy Jagdish^b, El Nazeer A. Salim^c^a Department of Surgery, College of Medicine and Health Sciences, UAE University, Al-Ain, United Arab Emirates^b Department of Radiology, Al Rahba Hospital, Abu Dhabi, United Arab Emirates^c Department of Surgery, Al Rahba Hospital, Abu Dhabi, United Arab Emirates

ARTICLE INFO

Article history:

Received 28 May 2018

Received in revised form

26 June 2018

Accepted 28 June 2018

Available online 5 July 2018

This paper was presented as a poster in the 19th European Congress of Trauma and Emergency Surgery, Valencia, Spain, May 2018.

Keywords:

Adult
Bicycling
Hernia

ABSTRACT

The term handlebar hernia had been applied to describe the traumatic hernia that result from a handlebar-like blunt objects. The force of the blunt trauma is insufficient to breach the elastic skin, yet, it can cause abdominal wall musculature disruption. Serious intraabdominal injuries can result which may be evident at the time of trauma or may be delayed. Many physicians may misinterpret the irreducible hernia as a hematoma or soft tissues contusion following the trauma.

Computed tomography (CT) scan remains the gold standard diagnostic tool for evaluation of those patients. Nevertheless, accurate diagnosis can only be made by repeated, careful physical examination.

Herein, we present a rare case of true traumatic bicycle handlebar hernia in an adult lady. She is the first reported case in the literature to be treated conservatively. We also reviewed the literature on true traumatic bicycle handlebar hernia in adult patients.

Copyright © 2018 The Emergency Medicine Association of Turkey. Production and hosting by Elsevier B.V. on behalf of the Owner. This is an open access article under the CC BY-NC-ND license (<http://creativecommons.org/licenses/by-nc-nd/4.0/>).

1. Introduction

Traumatic abdominal wall hernia can result from either sharp or blunt trauma. Handlebar hernia is a rare type of blunt traumatic abdominal wall hernia.¹ Although, the force of the blunt trauma is insufficient to breach the elastic skin, yet, it can cause abdominal wall musculature disruption. The term handlebar had been applied to describe the traumatic hernia that result from a handlebar-like blunt object.² In the literature, the definition of handlebar hernia includes traumatic hernias resulting from all kinds of blunt forces and not only the handlebar (e.g. Road traffic collision (RTC), fall from a height, and impalement).^{2–4} True bicycle handlebar hernia should be applied only on hernia caused by a bicycle handlebar. The true bicycle handlebar hernia in an adult is very rare in contrast

with children handlebar hernia.⁵

On examination of those trauma patients, the presence of skin marks associated with the bulge caused by the hernia can be misdiagnosed as a hematoma or contusion. If the hernia was not diagnosed early during the initial assessment, serious complications can result as incarceration and strangulation of the hernia.⁶

Herein, we present a rare case of a true traumatic handlebar hernia in an adult lady. We also reviewed the literature about true bicycle traumatic handlebar hernia in adult patients.

2. Case presentation

A 38-year-old woman fell from her bicycle and hit her abdomen against the blunt end of the handlebar. She was presented to the Emergency Department complaining of abdominal pain and bulge at the site of handlebar impact. There was no history of previous abdominal operations and the patient stated that she had never had a localized abdominal swelling till the incident. On examination, her Glasgow coma score (GCS) was 15/15, afebrile, pulse rate 85 bpm, blood pressure 130/85 mmHg, and her respiratory rate was 14/minute. Abdominal examination revealed a prominent abdominal bulge in the left upper quadrant with a contusion mark

* Corresponding author. Department of Surgery, College of Medicine and Health Sciences, UAE University, P O Box 18532 Main Building of Post Office, Al Ain, Abu Dhabi, United Arab Emirates.

E-mail addresses: ahefny@uaeu.ac.ae (A.F. Hefny), jjagdish@seha.ae (J. Jagdish), esalim@seha.ae (E.N.A. Salim).

Peer review under responsibility of The Emergency Medicine Association of Turkey.

displaying the imprint of the bicycle handlebar. The swelling increases in size on coughing and disappears on lying down (reducible). Blood investigation revealed haemoglobin of 10.7 g/L, total white blood cell count of $7.6 \times 10^9/L$, and serum amylase of 51 IU/L. Ultrasound scan was not performed.

Intravenous contrast enhanced CT scan of the abdomen and pelvis revealed a wide-necked left para midline abdominal wall hernia containing a loop of transverse colon. The neck of the hernia appeared interposed between the medial fibres of the left rectus abdominis muscle. There was diffuse fat stranding centred on the hernia at the site of handlebar skin injury which indicates acute event (Fig. 1). There was no evidence of bowel injury as free intraperitoneal air (FIA).

The patient was diagnosed to have a bicycle handlebar hernia. The patient was admitted to the surgical department for observation and was treated conservatively. She was discharged from the hospital to be follow up in the surgical clinic for subsequent elective repair.

3. Discussion

The true adult bicycle handlebar hernia in adults is a very rare type of traumatic abdominal wall hernia. To our knowledge, this is the 10th reported case in the English literature of a true traumatic bicycle handlebar hernia in adults (Table 1).

Bicycle handlebar hernia are more common in paediatric population but very rare in adults' population.⁵ We think that, the force of trauma of the handlebar may not be enough to disrupt the well-developed muscles in adults in contrast with children with less developed muscles.

Intraabdominal injuries can result from the blunt force of the handlebar, crushing of the bowel between the handlebar and spine, or incarceration and strangulation of the hernia.^{6,7} Two patients were involved in RTC while they were riding the bicycle. This high injury trauma causes more severe injuries to those patients. One of them had an associated diaphragmatic hernia and the other had a liver laceration.^{8,9}

In all the reported cases, there was a clear history of bicycle

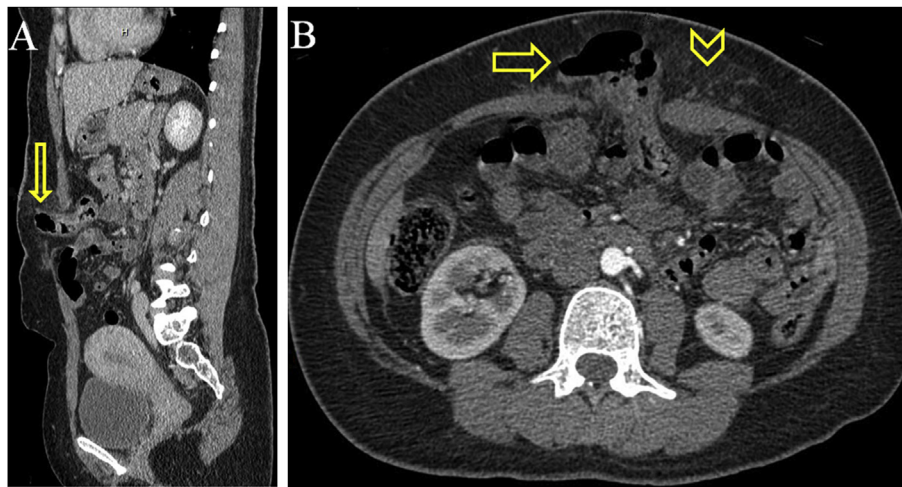


Fig. 1. (A) CT scan (sagittal view) showing protrusion of loops of bowel through the abdominal wall defect at the skin site of bicycle handlebar injury (arrow). (B) Axial CT scan of the abdomen showing protrusion of loops of bowel through a defect along the medial fibers of the left rectus muscle (arrow). There is fat stranding corresponding to the site of skin handlebar injury (arrow head) indicating an acute event.

Table 1

Reported cases of adult's true bicycle handlebar hernia.

Reference	Age/sex	Mechanism	site	CM	Irreducible swelling	Peritoneal signs	CT Finding	Diagnosis	treatment	Operative findings
Orland ⁹	35/M	FOBH & RTC	U A	Present	No	No	FD, FIA	Early	Laparotomy	SBP, liver laceration
Ghosh ¹³	25/M	FOBH	L A	Present	Yes	No	FD, bowel protrusion	Early	Laparotomy	SBP (Ileum)
Akhtar ⁸	45/M	FOBH & RTC	LUQ	Present	No	No	FD, DH	Early	Laparotomy	DH
Chan ⁷	54/M	FOBH	LLQ	Present	Yes	No	FD, FIA, bowel protrusion	Early	Laparotomy	SBP, (Ileum)
Truong ¹¹	29/M	FOBH	RUQ	Present	Yes	No	FD, omentum protrusion	Early	Laparotomy	tear serosa
Goh ⁶	33/M	FOBH	LLQ	Present	Yes	Yes	FD, omentum protrusion	Late	Laparotomy	SBP (Jejunum)
Okamoto ¹	36/M	FOBH	LLQ	Present	Yes	No	FD, bowel protrusion	Late	Laparotomy	tear serosa
Cullinane ¹²	24/M	FOBH	LUQ	Present	Yes	No	FD, FIA	Late	Laparotomy	Stomach perforation
Maunola ¹⁰	19/M		RLQ	Present	–	–	–	–	–	–
Hefny et al. (present study)	38/F	FOBH	LUQ	Present	No	No	FD, bowel protrusion	Early	Conservative	–

Ref = Reference number, M = Male, F = Female, FOBH = Falling on bicycle handlebar, RLQ = Right lower quadrant, LUQ = Left upper quadrant, LLQ = Left lower quadrant, RUQ = Right upper quadrant, LA = Lower abdomen, UA = Upper abdomen, CM = Contusion marks, FD = Fascial defect, FIA = Free intraperitoneal air, DH = Diaphragmatic hernia, SBP = Small bowel perforation.

handlebar trauma to the abdominal wall. They had a contusion skin marks of the handlebar over a bulge which was not visible before the trauma.^{10,11} In six patients (60%) there was an irreducible bulge at the site of the injury. Many physicians can misinterpret the irreducible hernia as a contusion of the soft tissues or hematoma following the trauma which can delay the diagnosis. The delay in the diagnosis of the hernia carries a higher risk for complications due to the possibility of obstruction or strangulation. The clinical presentation of abdominal signs of peritoneal irritation due to bowel perforation or bleeding is not always detected during the initial examination. In three patients (30%) peritoneal signs were detected late (two of them had bowel perforation).^{6,12}

Most of the patients were hemodynamically stable and the initial blood investigations were normal. Point-of-care ultrasound (POCUS) can differentiate between the traumatic hernia and other causes of abdominal wall swellings as hematoma. The diagnosis in our patient was clear because of the reducibility of the swelling.

Since our patient was hemodynamically stable, a CT scan was performed to exclude other intraabdominal injuries.³ All the reported cases had a computed tomography (CT) scan evaluation. It is the gold standard diagnostic tool for evaluation of those patients. CT scan can detect the traumatic hernia and most of the associated injuries.^{2,3}

Three of the reported cases had a FIA on the CT scan without clinical evidence of peritonitis and all those patients had a bowel perforation at laparotomy. However, in two of the reported cases, CT scan did not detect the bowel perforation. In one of those two patients the diagnosis of peritonitis was made clinically, while the other patient had an irreducible hernia. At laparotomy, a small bowel perforation was detected in both patients.^{6,13}

In one study, preoperative CT scan could not detect FIA in 15% of patients with surgically proven bowel perforation.¹⁴ This could be due to the difference in the CT scan techniques and CT slice thickness that can miss small FIA (new CT scan machines are able to detect even very small amount of FIA).¹⁴ Sometimes, bowel perforation occurs late after CT scan performance due to delayed bowel perforation resulting from hernia strangulation.⁶

On the other hand, CT scan may detect free intraperitoneal air without bowel perforation in trauma patients which can lead to non-therapeutic laparotomy.¹⁵

Accurate diagnosis can only be made by repeated, careful physical examination to avoid missing bowel perforations.²

In most of the patients, definitive treatment requires surgical repair of the hernia.² Eight patients (80%) had laparotomy to repair the fascial defect and to treat other intraabdominal injuries. Bowel perforation was detected in five patients of whom laparotomy was performed.

Early surgical repair is recommended by many authors to avoid the complications of the hernia.⁶ Synthetic mesh repair is the best treatment option.² Conservative management followed by elective repair may be adopted.⁵ Our patient was the only patient in the literature to be treated initially conservatively. We thought that, hernia was better to be repaired at later stage after resolving of muscle oedema and contusions.

4. Conclusions

Adult patients who fall from bicycle should be considered to have a significant mechanism of trauma that can cause serious abdominal injuries. Early recognition of the traumatic bicycle handlebar hernia is challenging and this condition needs a high index of clinical suspicion.

Repeated physical examination is essential to avoid missing bowel perforation.

Disclosure statement

The authors have no conflicts of interest. The authors are responsible for the content of the paper.

Funding

None.

Conflicts of interest

None.

Author contribution statement

All authors have actively participated in this research project, revised it for its intellectual content, and approved its final version.

References

1. Okamoto D, Aibe H, Hasuo K, et al. Handlebar hernia: a case report. *Emerg Radiol.* 2007;13:213–215.
2. Schoofs N, Van der Speeten K. Handlebar hernia: an uncommon cause of intra-abdominal lesions. *Acta Chir Belg.* 2013;113:293–297.
3. Losanoff JE, Richman BW, Jones JW. Handlebar hernia: ultrasonography-aided diagnosis. *Hernia.* 2002;6:36–38.
4. Metzдорff MT, Miller SH, Smiley P, et al. Blunt traumatic rupture of the abdominal wall musculature. *Ann Plast Surg.* 1984;13:63–66.
5. Decker S, Engelmann C, Krettek C, et al. Traumatic abdominal wall hernia after blunt abdominal trauma caused by a handlebar in children: a well-visualized case report. *Surgery.* 2012;151:899–900.
6. Goh SC, Welch C, Houlden CJ, et al. Traumatic bicycle handlebar hernia. *Eur J Emerg Med.* 2008;15:179–180.
7. Chan TY, Chien LC, Hong MY, et al. Handlebar hernia. *QJM.* 2011;104:67.
8. Akhtar MS, Beg MH, Ali SA, et al. Post-traumatic synchronous twin intermuscular abdominal and diaphragmatic hernias: a rare presentation. *Indian J Chest Dis Allied Sci.* 2012;54:193–195.
9. Orland M. Forward fall. Get a handle on handlebar injuries. *JEMS.* 2013;38:24–26.
10. Maunola R, Kekomaki M. Traumatic hernia. 2 cases of traumatic subcutaneous rupture of the abdominal wall. *Acta Chir Scand.* 1965;130:256–258.
11. Truong T, Costantino TG. Images in emergency medicine. Traumatic abdominal wall hernias. *Ann Emerg Med.* 2008;52(182):6.
12. Cullinane DC. Incarcerated, strangulated handlebar hernia. *Injury.* 2000;31:551–553.
13. Ghosh SC, Nolan GJ, Simpson RR. A concealed small bowel perforation in an adult secondary to bicycle handlebar trauma. *Ann R Coll Surg Engl.* 2013;95:e69–e70.
14. Lacalamita MC, Moschetta M, Mancini ME, et al. Role of CT in the diagnosis of jejunal-ileal perforations. *Radiol Med.* 2014;119:651–657.
15. Hefny AF, Kunhivalappil FT, Matev N, et al. Usefulness of free intraperitoneal air detected by CT scan in diagnosing bowel perforation in blunt trauma: experience from a community-based hospital. *Injury.* 2015;46:100–104.