



## Case Report

# Ultrasound diagnosis of cardiac rupture caused by mechanical chest compression

Ying-Tai Shih <sup>a</sup>, Chai-Hock Chua <sup>b</sup>, Sheng-Wen Hou <sup>a</sup>, Li-Wei Lin <sup>a</sup>, Chee-Fah Chong <sup>a, c, \*</sup>

<sup>a</sup> Department of Emergency Medicine, Shin-Kong Wu Ho-Su Memorial Hospital, Taipei City, Taiwan

<sup>b</sup> Department of Cardiovascular Surgery, Shin-Kong Wu Ho-Su Memorial Hospital, Taipei City, Taiwan

<sup>c</sup> School of Medicine, Fu Jen Catholic University, New Taipei City, Taiwan



## ARTICLE INFO

## Article history:

Received 31 January 2018

Received in revised form

20 February 2018

Accepted 22 February 2018

Available online 26 February 2018

## Keywords:

Cardiac rupture

Mechanical chest compression

Ultrasound

## ABSTRACT

A 74-year-old male with chronic kidney disease presented to the emergency department with asystole. Mechanical chest compression was started immediately using a piston-type thumper device. The initial potassium level was 7.7 mEq/L and bedside point-of-care ultrasound (POCUS) revealed no pericardial fluid. With standard resuscitation and anti-hyperkalemia treatment, return of spontaneous circulation (ROSC) was achieved within 10 minutes of compressions. At 15 minutes post-ROSC, the patient went into pulseless electrical activity. A repeated POCUS discovered massive pericardial fluid suggesting the presence of cardiac tamponade. Bedside pericardiectomy was performed followed by open thoracotomy. Laceration of the right ventricular wall adjacent to the fracture site of sternum was found, implicating that it was the complication of mechanical chest compression. After surgical repair and intensive post-operative care, the patient survived with full conscious recovery at day 6 of admission. Our case emphasizes the importance of POCUS in resuscitation, especially when the patient's condition deteriorates unexpectedly.

Copyright © 2018 The Emergency Medicine Association of Turkey. Production and hosting by Elsevier B.V. on behalf of the Owner. This is an open access article under the CC BY-NC-ND license (<http://creativecommons.org/licenses/by-nc-nd/4.0/>).

## 1. Introduction

Although it is still under debate that mechanical chest compression devices (MCCDs) cause more benefit or more harm compared with manual chest compression,<sup>1</sup> they are increasingly used during cardiopulmonary resuscitation (CPR) to ensure reliable, continuous chest compressions in patients with out-of-hospital cardiac arrest (OHCA) or in-hospital cardiac arrest (IHCA). However, despite their increasing popularity, little evidence exists for their effectiveness. Reported complications for MCCDs included skeletal chest injuries,<sup>2</sup> pneumothorax,<sup>3</sup> laceration of spleen or liver,<sup>4–6</sup> and stomach rupture.<sup>7</sup> Laceration of heart chambers was rarely reported, if any. We report a serious complication of a MCCD causing right ventricular (RV) laceration which

led to clinical deterioration after an initially successful resuscitation. Physicians should be aware of such severe complication of MCCDs if patients deteriorate unexpectedly or remain unstable after CPR.

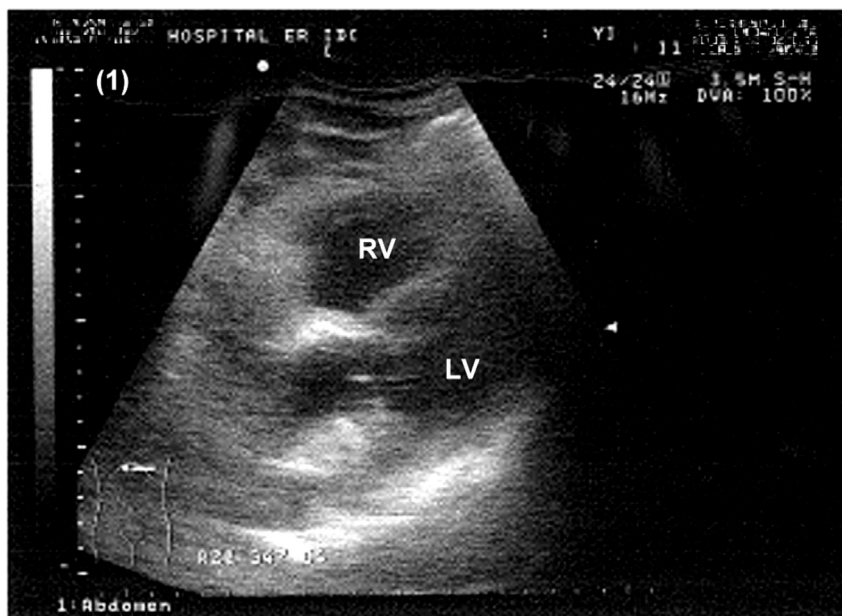
## 2. Case report

A 74-year-old man suffered a cardiac arrest en route to hospital. His weight and height were 47 kg and 150 cm respectively. His past medical history was significant for renal cell carcinoma s/p surgical resection and chronic kidney disease with baseline creatinine level of 5.3 mg/dL. Upon arrival to the ED, OHCA with asystole was confirmed and CPR was started immediately using a piston-type thumper device (LIFE-STAT® Hands-Free CPR System) followed by 1 mg epinephrine intravenously and endotracheal intubation. The bedside point-of-care ultrasound (POCUS) revealed no pericardial fluid (Fig. 1), no pleural fluid, and no ascites. As part of the OHCA routines, a rapid point-of-care blood gas analysis showed that his potassium level was 7.7 mEq/L (venous blood sample: pH 7.12, PO<sub>2</sub> 14.8 mm Hg, PCO<sub>2</sub> 82.1 mm Hg, HCO<sub>3</sub> 13.9 mEq/L). Boluses of sodium bicarbonate and calcium gluconate were given accordingly.

\* Corresponding author. Department Shin-Kong Wu Ho-Su Memorial Hospital, No.95 Wen-Chang Road Shi-Lin District, Taipei City, 111, Taiwan.

E-mail addresses: [incloud75531@hotmail.com](mailto:incloud75531@hotmail.com) (Y.-T. Shih), [m006513@ms.skh.org.tw](mailto:m006513@ms.skh.org.tw) (C.-H. Chua), [fasion@mac.com](mailto:fasion@mac.com) (S.-W. Hou), [dribliner@gmail.com](mailto:dribliner@gmail.com) (L.-W. Lin), [m002202@ms.skh.org.tw](mailto:m002202@ms.skh.org.tw) (C.-F. Chong).

Peer review under responsibility of The Emergency Medicine Association of Turkey.



**Fig. 1.** Bedside ultrasound of the heart during initial resuscitation. No pericardial fluid was found. RV: right ventricle; LV: left ventricle.

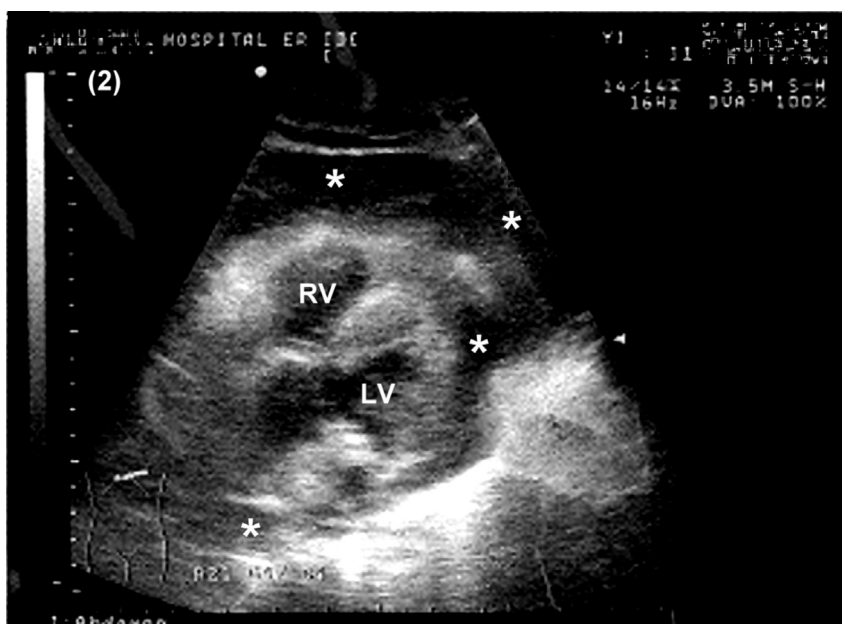
Return of spontaneous circulation (ROSC) was noted within 10 minutes of compressions. A 12-lead ECG showed sinus tachycardia of 132 bpm with peaked T waves. His systolic blood pressure (SBP) was kept around 90 mm Hg by 2 L of normal saline bolus and continuous norepinephrine infusion.

At 15 minutes post-ROSC, the patient lost his vital signs again and went into pulseless electrical activity (PEA). A repeated POCUS discovered massive pericardial fluid (Fig. 2). Bedside pericardiectomy was performed immediately evacuating 1000 mL of fresh blood with clots. His SBP returned to 90–120 mm Hg after pericardiectomy and transfusion of 4 units of packed RBC. Sinus tachycardia of 120–140 bpm was noted on the ECG monitor. The patient was then transferred to the operating room for open

thoracotomy. A laceration of the right ventricular wall adjacent to the fracture site of sternum was found, implicating that it was the complication of mechanical chest compression. After surgical repair and intensive post-operative care, the patient survived with full conscious recovery at day 6 of admission.

### 3. Discussion

Recent CPR guidelines emphasize on depth, rate, and continuity of chest compressions. Animal models and observational studies showed that the quality of manual chest compression might be inferior to mechanical chest compression.<sup>8–10</sup> A meta-analysis from 2013 which included 6538 OHCA patients claimed that the use of



**Fig. 2.** Bedside ultrasound of the heart 15 minutes after ROSC showing massive pericardial fluid (\*). RV: right ventricle; LV: left ventricle.

MCCDs correlates with a higher odds of ROSC, but long-term survival outcomes were not available.<sup>11</sup> On the other hand, in a systematic review from 2016 which involved 11,162 participants, the combined meta-analysis of MCCDs compared with manual chest compressions shown a better result with manual chest compression in rates of ROSC (for both OHCA and IHCA) and survival to discharge (for IHCA).<sup>12</sup> The 2014 Cochrane review also concluded that current evidence was insufficient to associate mechanical chest compressions during CPR with benefit or harm, and the widespread use of MCCDs was not supported.<sup>1</sup>

In our patient presented above, the initial cause of cardiac arrest was hyperkalemic asystole. However, about 15 minutes after ROSC, he lost his vital signs again due to PEA caused by massive pericardial fluid. Immediate pericardiectomy was performed, followed by emergent thoracotomy. During surgery, it was confirmed that the bloody pericardial fluid was a result of RV laceration by a sharp end of the fractured sternum. ED physicians and the consulting surgeon were able to act quickly in response to the patient's worsening condition because of the help of a well-done POCUS, which clearly demonstrated a significant interval change in the amount of pericardial fluids and probably signs of cardiac tamponade.

In conclusion, we believed that MCCDs should not be seen as a replacement for manual CPR, but rather a supplemental treatment in the overall management of cardiac arrest patients. Though rare, cardiac free wall rupture remained a probable complication of MCCDs that should not be forgotten. With appropriate POCUS training, emergency physicians should be able to detect pericardial fluids or signs of cardiac tamponade as part of the resuscitation protocol.

## Funding/conflict of interest

None declared.

## References

1. Brooks SC, Hassan N, Bigham BL, Morrison LJ. Mechanical versus manual chest compressions for cardiac arrest. *Cochrane Database Syst Rev*. 2014;2. CD007260.
2. Hoke RS, Chamberlain D. Skeletal chest injuries secondary to cardiopulmonary resuscitation. *Resuscitation*. 2004;63:327–338.
3. Hutchings AC, Darcy KJ, Cumberbatch GL. Tension pneumothorax secondary to automatic mechanical compression decompression device. *Emerg Med J*. 2009;26:145–146.
4. deRoos PP, Wiendels DR, Snellen JP. Fatal complication secondary to mechanical chest compression device. *Resuscitation*. 2009;80:1214–1215.
5. von Bary C, Hohenester S, Gaa J, Laugwitz KL. Liver laceration associated with the use of a chest compression device. *Resuscitation*. 2009;80:839.
6. Camden JR, Carucci LR. Liver injury diagnosed on computed tomography after use of an automated cardiopulmonary resuscitation device. *Emerg Radiol*. 2011;18:429–431.
7. Platenkamp M, Otterspoo LC. Complications of mechanical chest compression devices. *Neth Heart J*. Sep 2014;22:404–407.
8. Wik L, Kramer-Johansen J, Myklebust H, et al. Quality of cardiopulmonary resuscitation during out-of-hospital cardiac arrest. *J Am Med Assoc*. 2005;293:299–304.
9. Ikeno F, Kaneda H, Hongo Y, et al. Augmentation of tissue perfusion by a novel compression device increases neurologically intact survival in a porcine model of prolonged cardiac arrest. *Resuscitation*. 2006;68:109–118.
10. Casner M, Andersen D, Isaacs SM. The impact of a new CPR device on rate of spontaneous circulation in out-of-hospital cardiac arrest. *Prehosp Emerg Care*. 2005;9:61–67.
11. Westfall M, Krantz S, Mullin C, Kaufman C. Mechanical versus manual chest compressions in out-of-hospital cardiac arrest: a meta-analysis. *Crit Care Med*. 2013;41.
12. Li H, Wang D, Yu Y, Zhao X, Jing X. Mechanical versus manual chest compressions for cardiac arrest: a systematic review and meta-analysis. *Scand J Trauma Resuscitation Emerg Med*. 2016;24:10.