



## Controversies in the differential diagnosis of Brown-Sequard syndrome due to cervical spinal disease from stroke: A case series



Vaner Koksak, M.D. Assist Prof. <sup>a, \*</sup>, Ozcan Yavasi, M.D. Assist Prof. <sup>b</sup>

<sup>a</sup> Department of Neurosurgery, Recep Tayyip Erdoğan University, Research and Training Hospital, Rize, Turkey

<sup>b</sup> Department of Emergency Medicine, Recep Tayyip Erdoğan University, Research and Training Hospital, Rize, Turkey

### ARTICLE INFO

#### Article history:

Received 9 January 2017

Received in revised form

22 April 2017

Accepted 5 May 2017

Available online 3 June 2017

#### Keywords:

Brown-Sequard syndrome

Cervical cord

Herniated disc

Spinal epidural hematoma

Stroke

### ABSTRACT

Stroke is generally considered to be the first preliminary diagnosis in patients presenting with acute hemiparesis in the emergency department. But rarely in unexpected spontaneous neurological pathologies that may lead to hemiparesis. The data from 8 non-traumatic patients who underwent surgical treatment for brown-sequard syndrome (BSS) were reviewed retrospectively. All patients were initially misdiagnosed with strokes. Two of the patients had spinal canal stenosis, two had spinal epidural hematomas, one had an ossified herniated disc and three had soft herniated discs. None of the patients complained of significant pain at the initial presentation. All of the patients had a mild sensory deficit that was initially unrecognized. The pain of the patients began to become evident after hospitalization and, patients transferred to neurosurgery department. Cervical spinal pathologies compressing the corticospinal tract in one-half of the cervical spinal canal may present with only hemiparesis, without neck and radicular pain. If it's too late, permanent neurological damage may become inevitable while it is a correctable pathology.

Copyright © 2017 The Emergency Medicine Association of Turkey. Production and hosting by Elsevier B.V. on behalf of the Owner. This is an open access article under the CC BY-NC-ND license (<http://creativecommons.org/licenses/by-nc-nd/4.0/>).

### 1. Introduction

Brown-Sequard syndrome (BSS) is usually the result of trauma to one-half of the spinal cord, and constitutes 2–4% of all traumatic spinal cord injuries. BSS can also be associated with non-traumatic causes, such as a herniated cervical disc, cervical stenosis, and spontaneous cervical epidural hematoma (SCEH).<sup>1,2</sup> Although it has been described previously, the pure form of BSS is rarely found with ipsilateral motor paralysis and contralateral loss of pain and temperature. Contralateral hypoesthesia may not be noticed at first, and the sensory symptoms and pain can be mild because the neurological deficits are not fully formed.<sup>1,2</sup> Especially in overcrowded emergency departments, and in cases with insufficient patient history and incomplete neurological examination, hemiparesis can be the most evident complaint in patients with cervical narrow spinal canal pathologies without pain. Often in the

emergency department, a prediagnosis of ischemic stroke is generally preferred over BSS because acute cerebral ischemia (ACI) produces more fatal outcomes, and is seen more commonly. Moreover, BSS may mimic acute stroke, especially in patients with advanced age, leading to diagnostic challenges.<sup>3,4</sup> For this reason, we aimed to present our case series with cervical spinal disease for differential diagnosis of BSS from stroke.

### 2. Case presentations

We reviewed the data of patients, admitted to the emergency department between 2009 and 2014 with prediagnoses of ischemic stroke, and subsequently performed operation because the BSS has been identified in the neurosurgery department. These 8 patients presented with spontaneous unilateral hemiparesis of the upper and lower extremities, without significant cervical pain. In all of the patients, aroused the suspicion of cerebral ischemia, and they initially underwent cranial computed tomography (CT). Since these CTs did not reveal ischemia, they each underwent diffusion weighted magnetic resonance imaging (DW-MRI) of the brain. In light of the examinations and normal CT results, and DW-MRI results at the acute stage, the patients were believed to have ischemic

\* Corresponding author. Recep Tayyip Erdoğan University, Research and Training Hospital, Department of Neurosurgery, 53020 Rize, Turkey.

E-mail address: [vanerkoksal@hotmail.com](mailto:vanerkoksal@hotmail.com) (V. Koksak).

Peer review under responsibility of The Emergency Medicine Association of Turkey.

stroke and were admitted to the neurology department. The failure to detect other clinical findings of cerebral ischemia, and the increased degree of pain in some cases, negated the prediagnosis of ischemia, and all cervical MRIs results were showed findings, which can cause BSS. Subsequent to the clarification of the definitive diagnosis, the patients were transferred to and operated in the neurosurgery department.

There were six (75%) males and two (25%) females cases, and the median age was 62 years (range; 54–85). Seven of the cases had clinical complaints which first began during daily activities. Only one had a history of falling (from the same level) due to a loss of balance. In this case, at first, the trauma history was thought to be responsible for the symptoms. Then, hemiparesis was thought to be responsible for the falling due to the normal soft tissues and vertebral bones of the cervical spine on the radiography and cervical CT. But then, spinal cord edema due to acute trauma was seen on T2 sagittal MRI of the cervical spine. In two cases, SCEH was found to be the cause of the BSS.

None of the patients complained of significant neck or cervical radicular pain at the initial presentation, but after presenting to the emergency department, neck pain is manifested within 3–7 days cause by epidural bleeding became within 3–7 days because patient did not have cervical CT or MRI at initial presentation. The cervical MRIs and CT images (if any) of all of the cases are shown in Fig. 1. The cervical MRIs revealed significant multi-level spinal

stenoses in four of the cases, and prior single-level herniated disc in two of the cases (Fig. 1). Based on the reassessment of the CTs, three of the patients with stenotic cervical spinal canal showed asymmetrical ossification of the posterior longitudinal ligament (ossified PLL), markedly narrowing the canal at the lateral recesses. In one case with cervical disc herniation (CDH), the MRI scan displayed edema in the spinal cord (Fig. 1; case 8). The radiographs of the patients with stenotic spinal canals revealed spinal spondylosis.

The clinical complaints of the SCEH patients resolved over time, after surgery. One SCEH case had a history of warfarin and acetylsalicylic acid use, while the other case had no facilitating cause. Each of these cases performed a hemilaminectomy on the epidural hemorrhage side. The one-year follow-up of the cases that received hemilaminectomy of the cervical spine exhibited no deformities in the cervical area. Six of the patients completely recovered, one patient with SCEH and one with CDH showed incomplete recovery. The demographic data of all of the patients and outcomes are shown in Table 1.

### 3. Discussion

In the present study, we focused on the causes of non-traumatic BSS associated with pathologies of the upper spinal cord, and how the differential diagnosis between ischemic stroke and non-traumatic BSS can be done. Pathologies affecting the cervical

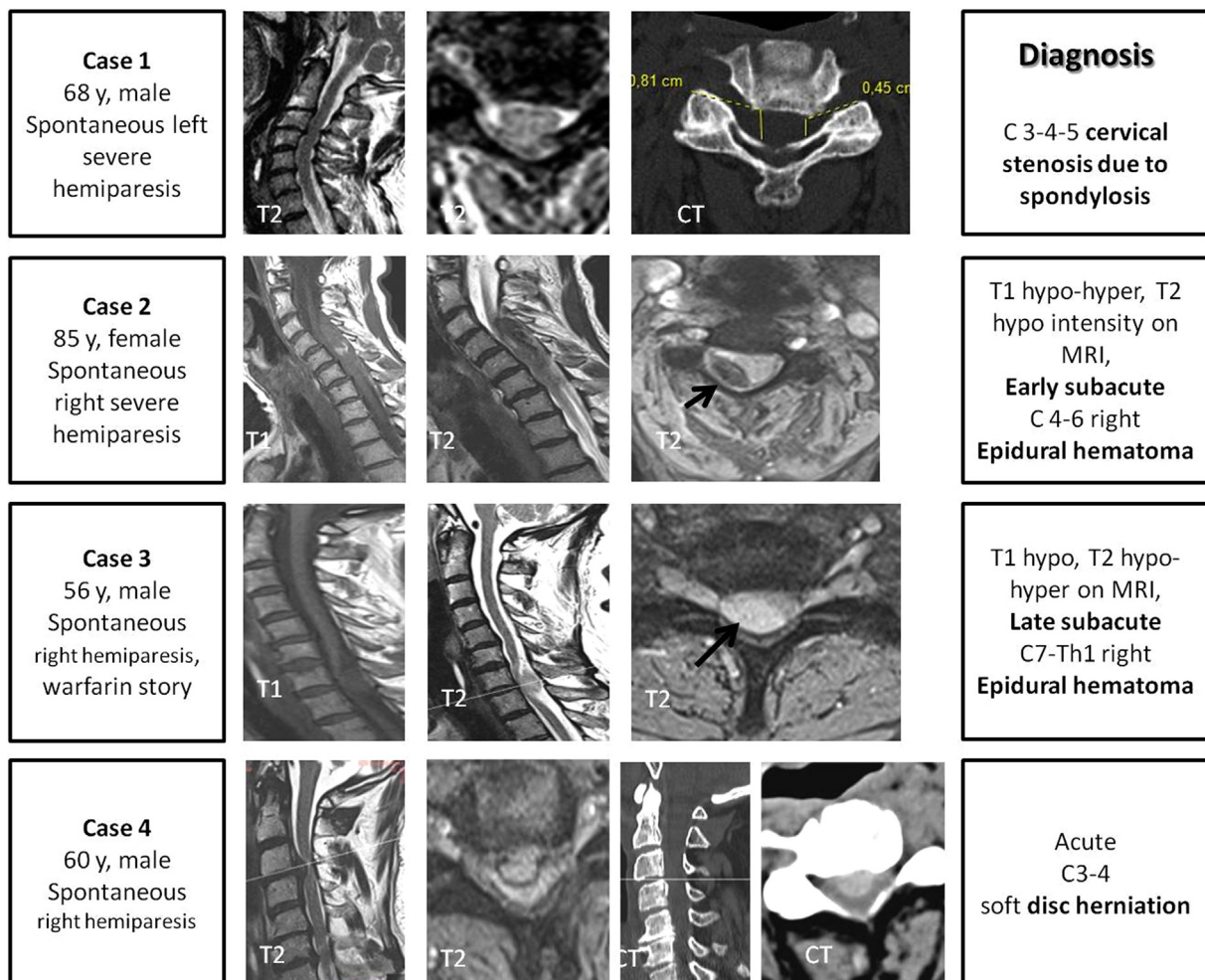


Fig. 1. (Parts 1 and 2). Clinical and radiographic characteristics of all 8 cases.

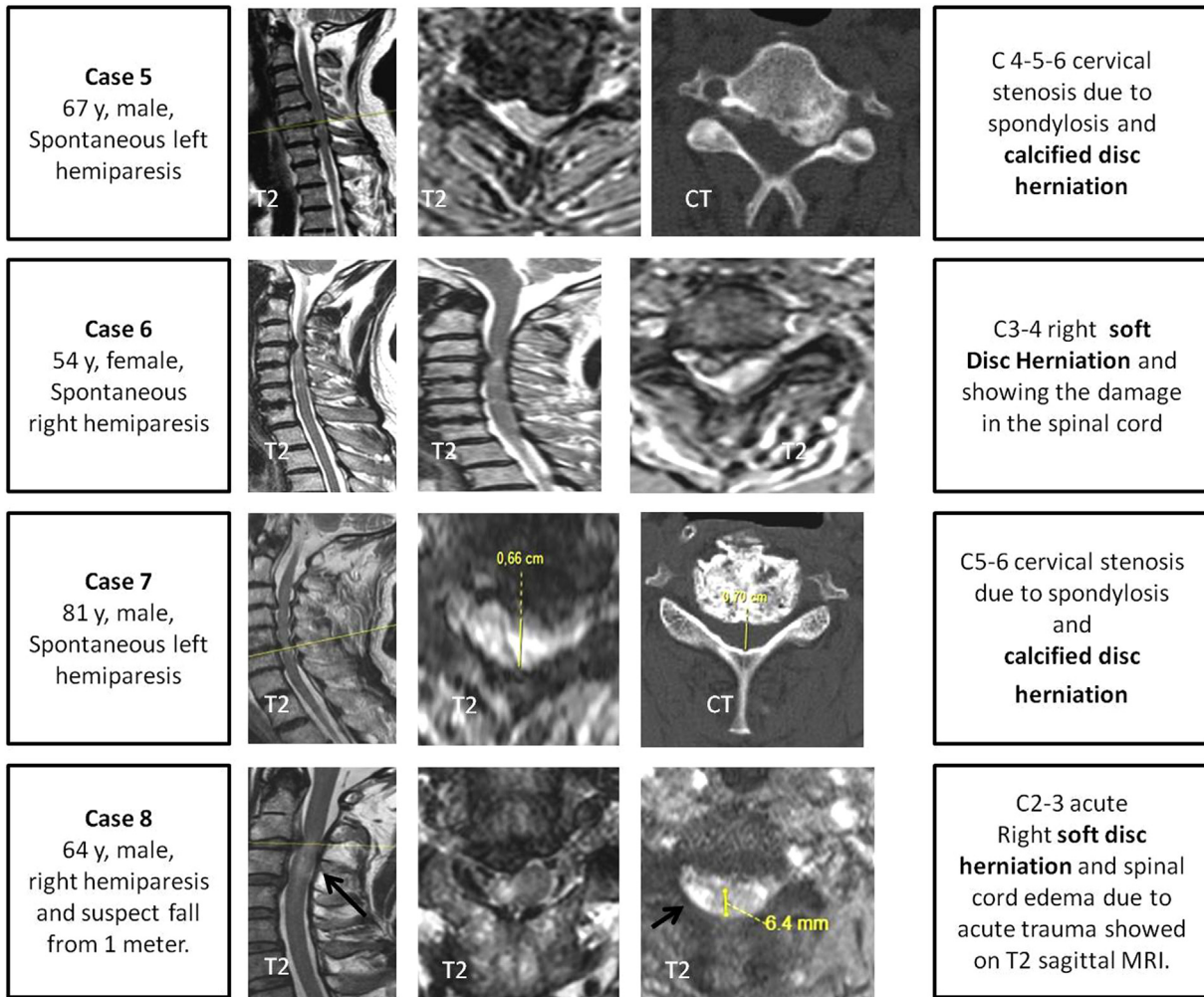


Fig. 1. (continued).

spinal canal may cause various clinical symptoms, depending on their location, such as compression of the nerve root and partial or complete compression of the spinal cord. Thus, incomplete involvement of the lateral half of the spinal canal may lead to a

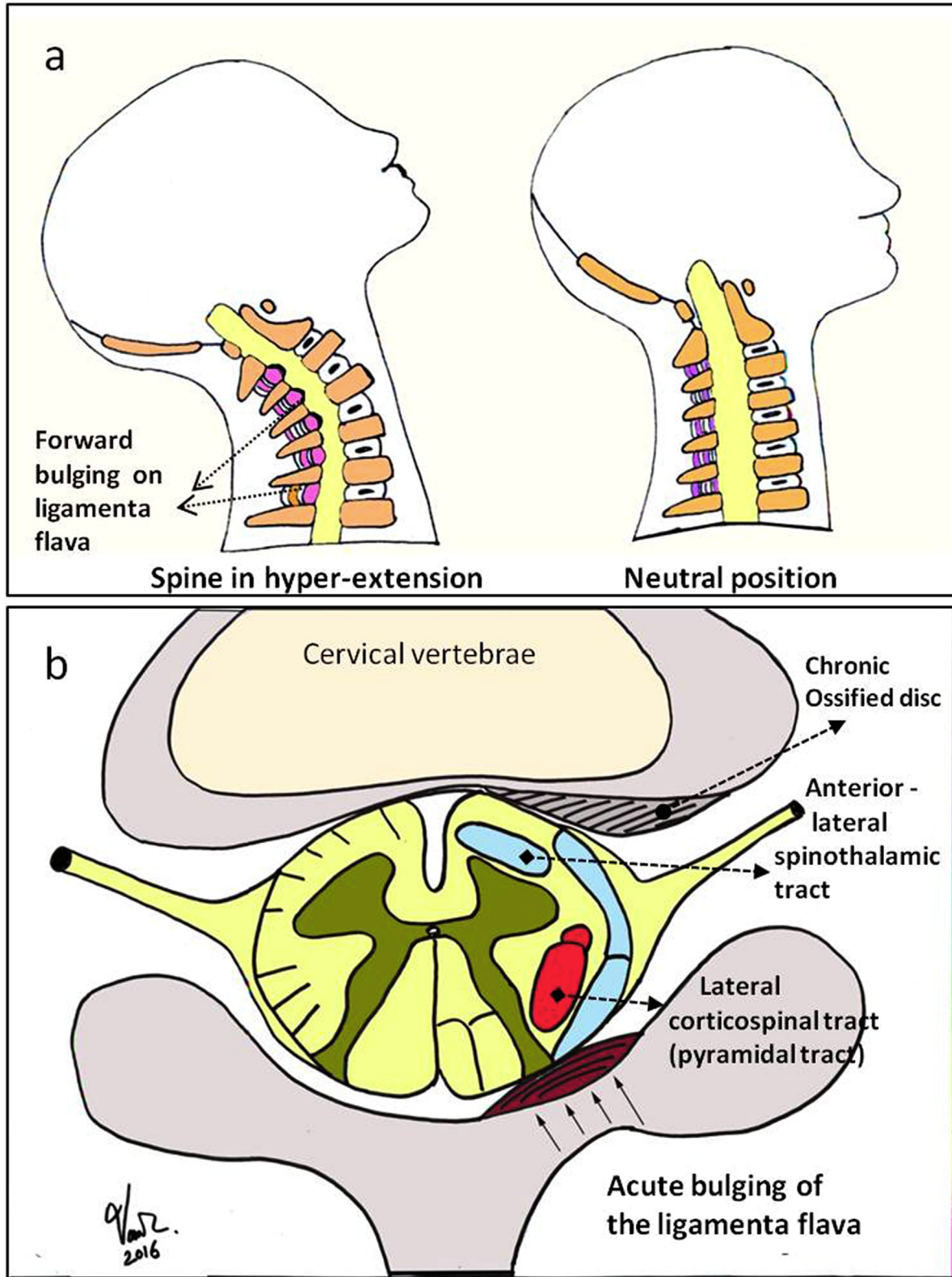
clinical profile of BSS.<sup>1,5</sup> BSS is defined as reduced or loss of motor function due to ipsilateral damage in the corticospinal tract, and decreased or loss of pain and temperature sensation in the contralateral extremity, with conservation of deep sensation.<sup>6</sup>

Table 1

Demographic Data of All 8 patients. ED: Emergency Department, CL: Contralateral, Hyp: hypoesthesia, CR: complete recovery, IR: incomplete recovery, SCEH: spontaneous cervical epidural hematoma, CDH: cervical disc herniation, TL: Total laminectomy, HL: Hemilaminectomy, ACD: Anterior cervical discectomy and fusion.

Case	Age/Sex	Initial symptoms	The interval between the clinical onset and initial clinical examination in EU	Sensory deficits of these patients	Level of affected on spine	Diagnosis	Timing of surgery	Surgical method	Outcome
1	68/M	Painless hemiparesis	Acute 6–8 h	CL C4–C5 Hyp	C3–4–5	Stenosis due to spondylosis	2 day	Two level TL	CR
2	85/F	Mild neck pain and hemiparesis	Subacute 12–16 h	CL C4–C5 Hyp	C4–5–6	SCEH	3 day	Two level HL	CR
3	56/M	Mild neck pain and hemiparesis	Subacute 24–36 h	CL C7 Hyp	C7–Th1	SCEH	7 day	One level HL	IR
4	60/M	Mild radicular pain and hemiparesis	Acute 6–8 h	CL C4 Hyp	C3–4	Soft CDH	3 day	ACD	CR
5	67/M	Painless hemiparesis	12–16 h	CL C5–C6 Hyp	C4–5–6	Ossified CDH	2 day	Two level TL	CR
6	54/F	Mild neck pain and hemiparesis	10–12 h	CL C4 Hyp	C3–4	Soft CDH	2 day	ACD	CR
7	81/M	Painless hemiparesis	24–36 h	CL C6 Hyp	C5–6	Stenosis due to spondylosis	3 day	One level TL	CR
8	64/M	Mild neck pain and hemiparesis	8–10 h	CL C3 Hyp	C2–3	Soft CDH	5 day	ACD	IR





**Fig. 2.** The neural tracts affected by hyperextension in one case of a stenotic cervical spinal canal at the level of the lateral recess are shown. The relationships of the stenosis with the corticospinal and spinothalamic tracts are outlined.

The most important findings differentiating between an ischemic stroke and BSS were speech disorders and facial paralysis in the clinical findings of ischemic stroke, which were not observed in BSS.<sup>4</sup> Generally, cervical or thoracic spinal cord blunt traumas are responsible for BSS; however, it is rarely caused by penetrating traumas.<sup>1,6,7</sup> In some instances, BSS associated with blunt trauma may occur due to a herniated disc, direct bone compression, vascular compression arising from direct compression, ischemia or direct stretching of the PLL of the spinal cord.<sup>7</sup> Although uncommon, incomplete BSS can also occur as a result of non-traumatic injury.<sup>8</sup>

Because the spinal cord compression appears before the neural root compression in such cases, radicular pain symptoms are not often present. Contralateral deficits are associated with the degree of compression and exact location. Since the corticospinal tract is anatomically located most laterally and posteriorly within the spinal cord, it is the first to be affected by lateral and posterior compression (Fig. 2b). The spinothalamic tract is located closest to the central and anterior portion of the spinal cord; therefore, the severity of sensory dysfunction may be unclear in some cases. Moreover, the spinal cord can be easily affected by the bulging of the ligamentum flavum in the narrow spinal canal (Fig. 2a and b) and also there may be a hemorrhage in posterior-lateral part of the spinal canal.<sup>6–9</sup> The degree of spinal cord compression varies among patients; however, one-half of the spinal cord should be completely damaged to observe the BSS triad.<sup>7,9</sup> When the damage affects the corticospinal tract more while influencing the spinothalamic tract less, due to incomplete compression, diagnostic difficulty and confusion may occur. The resulting pathology and the affected neural tracts are shown in the anatomical drawing in Fig. 2b.

SCEH, cervical disc inflammation, tumours, cervical spinal canal stenosis, extradural primary or metastatic tumours and vascular malformation may lead to BSS via the mass effect; however, the clinical profile may be confused with ischemic stroke because of the symptom of hemiparesis.<sup>1,8–11</sup> Ischemic stroke cases often present with accompanying clinical symptoms, depending on the affected cerebral region. Changes in consciousness, speech disorders and impaired vision, albeit temporary in nature, can be seen with hemiparesis.<sup>4</sup>

It is very rare for cases of CDH to present with an acute BSS clinical profile,<sup>6</sup> and Stookey was the first to describe CDH as part of the BSS etiology. In addition, Jomin et al. found the combination of BSS and CDH in 2.6% of patients, with the pathology at the C5–6 and C6–7 levels.<sup>7</sup> In our study, CDH was at the C2–3, C3–4, C4–5 and C5–6 levels. In neurosurgery practice, it is common to observe stenosis associated with degenerative changes at the C5–6 and C6–7 levels on cervical MRIs, which do not induce long-standing neurological symptoms. In some cases, spinal canal stenosis may go undetected until the disappearance of the cerebrospinal fluid (CSF) surrounding the spinal cord, and the involvement of the nerve roots.<sup>11</sup> In a review by Kobayashi et al. including 18 CDH patients, the mean age of the BSS diagnosis was 48 years old.<sup>6</sup> They noted that none of the cases had history of trauma, and the clinical symptoms developed subsequent to normal daily activities. Apparently, a heavily compressed spinal cord loses the ability to move, thereby suffering mechanical damage upon the slightest hyperextension (Fig. 2a). Some studies underscore this, reporting the onset of clinical symptoms in response to a simple hyperextension maneuver.<sup>11</sup> In our study, the history of one of the patients, who was 81 years old with spinal stenosis, revealed that he had started to experience the clinical symptoms during routine daily movement.

Radiographic findings characteristic of paramedian CDH have commonly been seen in the presence of cervical spinal stenosis.<sup>6,11</sup> Our cases were radiographically determined to be paramedian CDH

with stenotic cervical canals at the lateral recess level (cases 1, 5 and 7), and the neurological deficits were thought to result from a simple rotation movement coupled with hyperextension. The increased pressure secondary to edema in the spinal cord causes ischemia.<sup>6,9,11</sup> In some cases, the tight adhesion between the dura mater and the PLL may lead to spinal cord compression.<sup>6</sup> Our cases with stenotic spinal canal showed characteristic radiographic findings consistent with the literature (Fig. 1; cases 1, 5 and 7).

SCEH is a rare pathology, generally presenting with acute neck pain subsequent to mild radicular pain. The formation of the clinical picture may take 2–3 days.<sup>12</sup> The second most common symptom is fatigue in the arms. The paresis may become aggravated over minutes or days, and rarely, may resolve.<sup>13,14</sup> The etiology of SCEH includes undiagnosed, acquired or congenital coagulopathies, such as hemophilia, anticoagulant use, hypertension, neoplasm, arteriovenous malformation, trauma, post-operative complications, cough, vomiting, sneezing or weight lifting, which increase venous pressure.<sup>15</sup> However, in 40% of the patients with such hemorrhages, no etiology can be identified, and they are classified as having idiopathic SCEH.<sup>10,13–15</sup> The vascular vulnerability may be responsible.<sup>13</sup> These hemorrhages often form at the cervicothoracic junction. A bilateral clinical profile is more commonly seen, while hemiparesis is a rare event.<sup>12</sup> Posterolateral acute compression of the spinal cord may lead to BSS. However, it may fill the spinal canal upwards. Hematoma is usually spanning over 2–3 segments, and the clinical presentation may vary, depending on the size, location of the hematoma and duration of the hemorrhage (hemorrhage due to venous origin occurs slowly).<sup>14</sup> Based on our surgical findings, we concluded that there was venous vascular damage in the lower cervical segment, exhibiting hypermobility when compared to the thoracic spine.

SCEH can easily be diagnosed with a cervical MRI, and on T1-weighted MRI images an acute hemorrhage is seen as an iso-intense area. Since the fast field echo sequence showing acute hemorrhage was not included in our routine MRI sequences, we had no images of an acute hemorrhage; however, the subacute and chronic hemorrhages exhibited hyperintense appearances.<sup>13</sup> But in spite of technological advances, it may result in diagnostic challenges. In neurosurgery, SCEH is a very rare emergent condition; if not diagnosed early, it may result in disability. The standard treatment is the emergency drainage of the hematoma, and the interval between the onset of the SCEH symptoms and the surgical decompression determines the SCEH prognosis.<sup>12,13</sup>

Further, there are cases in the literature of patients receiving heparin therapy due to the misdiagnosis of ischemic stroke.<sup>8</sup> We observed no such case. If heparin therapy is given, there is an additional hemorrhage risk in case of surgery. Moreover, warfarin may increase the hemorrhage and deteriorate the clinical condition among those patients in whom the primary pathology is SCEH.

#### 4. Conclusion

Usually, chronic and sometimes acute cervical pathologies compressing one-half of the cervical spinal canal may present with only hemiparesis at first, without neck and radicular pain, especially in elderly patients. Thus, they masquerade as acute ischemic stroke. If there is any doubt following a detailed neurological examination, a cervical MRI should be incorporated into the routine assessment of such cases in the emergency department.

#### Conflicts of interest

The authors have no personal, financial, or institutional interest in any of the drugs, materials or devices described in this article.

## Funding

None Declared.

## Acknowledgments

The authors would like to thank associate professor İsa Kılıçaslan for his invaluable advice and revision.

## References

1. Lipper MH, Goldstein JH, Do HM. Brown-Sequard syndrome of the cervical spinal cord after chiropractic manipulation. *AJNR Am J Neuroradiol*. 1998;19(7):1349–1352.
2. Akimoto T, Yamada T, Shinoda S, Asano Y, Nagata D. Spontaneous spinal epidural hematoma as a potentially important stroke mimic. *J Cent Nerv Syst Dis*. 2014;6:15–20.
3. Sayer FT, Vitali AM, Paquette S, Honey CR. Isolated C3–C4 disc herniations present as a painless myelopathy. *Spine J*. 2008;8(5):729–731.
4. Maldonado NJ, Kazmi SO, Suarez JL. Update in the management of acute ischemic stroke. *Crit Care Clin*. 2014;30(4):673–697.
5. Rumana CS, Baskin DS. Brown-Sequard syndrome produced by cervical disc herniation: case report and literature review. *Surg Neurol*. 1996;45(4):359–361.
6. Kobayashi N, Asamoto S, Doi H, Sugiyama H. Brown-Sequard syndrome produced by cervical disc herniation: report of two cases and review of the literature. *Spine J*. 2003;3(6):530–533.
7. Jomin M, Lesoin F, Lozes G, Thomas 3rd CE, Rousseaux M, Clarisse J. Herniated cervical discs. Analysis of a series of 230 cases. *Acta Neurochir (Wien)*. 1986;79(2–4):107–113.
8. Kim SW, Ju C II, Kim HS, Kim YS. Brown-Sequard syndrome caused by a cervical synovial cyst. *J Korean Neurosurg Soc*. 2014;55(4):215–217.
9. Lim E, Wong YS, Lo YL, Lim SH. Traumatic atypical Brown-Sequard syndrome: case report and literature review. *Clin Neurol Neurosurg*. 2003;105(2):143–145.
10. Seon H-J, Song M-K, Han J-Y, Choi I-S, Lee S-G. Spontaneous cervical epidural hematoma presenting as brown-Sequard syndrome following repetitive Korean traditional deep bows. *Ann Rehabil Med*. 2013;37(1):123–126.
11. Chen P-Y, Lin C-Y, Tzaan W-C, Chen H-C. Brown-Sequard syndrome caused by ossification of the ligamentum flavum. *J Clin Neurosci Off J Neurosurg Soc Australas*. 2007;14(9):887–890.
12. So G, Debata A, Baba S, Tsunoda K, Suyama K, Nagata I. Spontaneous cervical epidural hematoma presenting with hemiparesis following neck extension: a case report. *No Shinkei Geka*. 2008;36(8):731–734.
13. Ofluoglu E, Ozdemir A, Toplamaoglu H, Sofuoglu E. Spontaneous cervical epidural hematoma causing Brown-Sequard syndrome: case report. *Turk Neurosurg*. 2009;19(1):99–102.
14. Kreppel D, Antoniadis G, Seeling W. Spinal hematoma: a literature survey with meta-analysis of 613 patients. *Neurosurg Rev*. 2003;26(1):1–49.
15. Vitali AM, Steinbok P. Spontaneous spinal epidural hematoma following weight lifting. *Can J Neurol Sci*. 2008;35(2):262–264.