



Case report

Pneumocephalus in a patient with multiple stab wounds

Yusuf Savran ^{a, *}, Volkan Karacam ^b, Basak Bayram ^c, Erdem Yaka ^d, Nuri Karabay ^e^a Department of Internal Medicine, Dokuz Eylul University Faculty of Medicine, Izmir, Turkey^b Department of Thoracic Surgery, Dokuz Eylul University Faculty of Medicine, Izmir, Turkey^c Department of Emergency Medicine, Dokuz Eylul University Faculty of Medicine, Izmir, Turkey^d Department of Neurology, Dokuz Eylul University Faculty of Medicine, Izmir, Turkey^e Department of Radiology, Dokuz Eylul University Faculty of Medicine, Izmir, Turkey

ARTICLE INFO

Article history:

Received 24 February 2016

Received in revised form

2 May 2016

Accepted 22 June 2016

Available online 4 July 2016

Keywords:

Air embolism

Intracranial gas

Pneumocephalus

Stab wounds

ABSTRACT

Pneumocephalus is a complication of trauma to the chest and many iatrogenic interventions. It may arise due to systemic air embolism or retrograde cerebral venous air embolism which is an extremely rare complication. We report a 26-years-old female patient who presented to the Emergency Department suffering of multiple stab wounds. She was in a state of shock and after first aid and evaluation she was operated successfully. In the early postoperative period generalized tonic clonic convulsions were observed following cardiopulmonary resuscitation due to sudden cardiovascular collapse. Brain computerized tomography demonstrated free air in intracranial and extracranial venous structures. Pneumocephalus was diagnosed which may be due to a wide spectrum of etiologies including thorax or spinal stab wounds, tube thoracostomy, cardiopulmonary resuscitation or even central venous catheterization. Unfortunately, the patient ended up with brain death despite all effort. In conclusion, we recommend physicians to be aware of this catastrophic complication while taking care of patients with stab wounds.

Copyright © 2016 The Emergency Medicine Association of Turkey. Production and hosting by Elsevier B.V. on behalf of the Owner. This is an open access article under the CC BY-NC-ND license (<http://creativecommons.org/licenses/by-nc-nd/4.0/>).

1. Introduction

Cerebral air embolism is a complication with a wide variety of etiologies that may cause catastrophic results.¹ Air entering the venous system classically embolizes to the right heart, pulmonary artery and at times through a patent foramen ovale or pulmonary arteriovenous shunt to the brain; an entity the so called 'paradoxical embolism'.² This is the most common scenario in clinical settings ending up with stroke due to arterial embolism in central nervous system. On the other hand, retrograde cerebral venous air embolism is a rare but fatal complication with few cases reported in literature.^{3,4}

We present a case of pneumocephalus in a patient with multiple stab wounds to the chest and paraspinal region.

2. Case presentation

A 26-year-old woman presented to the Emergency Department (ED) sustaining multiple stab wounds. On arrival, the patient was somnolent. At first evaluation she was hypotensive (66/38 mmHg) and tachycardic (136 beats/min). Other vital signs were: temperature 37 C, respiratory rate 32 breaths/min and oxygen saturation 82% on room air. Physical examination demonstrated a 2 cm-sized stab wound overlying left midclavicular pectoral region, two 2 cm-sized stab wounds on the left posterior hemithorax close to paraspinal region and a 1 cm-sized stab wound on the right posterior hemithorax close to paraspinal region all of which were extending into the subcutaneous tissue. There was no active bleeding but air bubble discharge was observed from the cut wounds on the left posterior hemithorax. Heart sounds were regular and no murmurs detected. Lung auscultation detected decreased breath sounds on the left hemithorax and portable chest x-ray revealed left traumatic hemothorax (Fig. 1). She was electively intubated and controlled mechanical ventilation support started. Emergently a tube thoracostomy was applied on the left side and 800 ml of hemorrhagic fluid and air was drained. The abdomen was not tender. No

* Corresponding author. Department of Internal Medicine, Dokuz Eylul University Faculty of Medicine, Mithatpasa cad. No:1606 Inciraltı Yerleskesi, 35340 Balçova, Izmir, Turkey. Tel.: +90 232 412 51 05, +90 505 658 60 40 (mobile).

E-mail address: yusuf.savran@deu.edu.tr (Y. Savran).

Peer review under responsibility of The Emergency Medicine Association of Turkey.

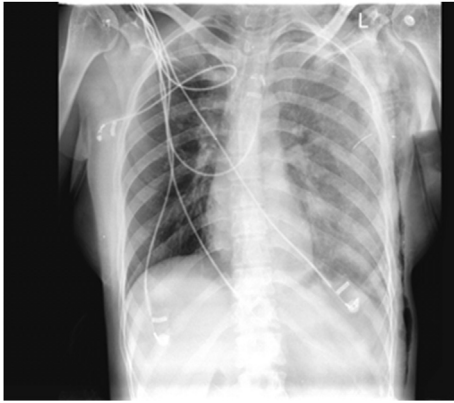


Fig. 1. Portable chest x-ray in the Emergency Service demonstrating left hemothorax.

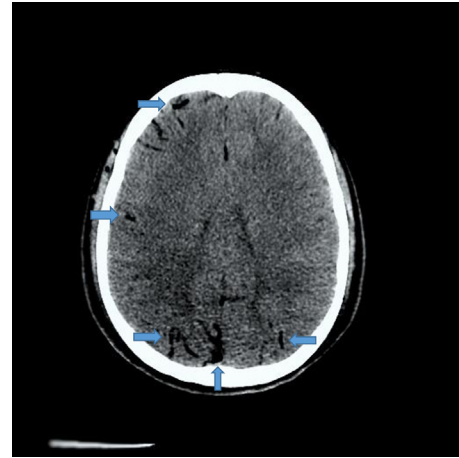


Fig. 2. Brain CT demonstrating pneumocephalus.

additional traumatic injuries were noted. A right subclavian venous catheter was inserted and fluid and erythrocyte transfusion applied. While receiving bolus fluid challenge and mechanical ventilation support she was urgently transferred into the operating room. Intraoperative exploration demonstrated no major vascular or heart laceration. Parenchymal stab wounds at left upper lobe anterior and lower lobe posterior segments and the stab wound at the right hemithorax were primarily sutured. Additionally a right tube thoracostomy was applied prophylactically. Upon intraoperative consultation Neurosurgery consultants recommended primary saturation of the paraspinal and stab wounds. The patient was transferred to the intensive care unit (ICU) and put on mechanical ventilation support after the operation. On admission to ICU the vital signs were: blood pressure 112/58 mmHg (without inotropic or vasopressor support), heart rate 100 beats/min, respiratory rate 16/min (on volume cycled controlled mechanical ventilation), temperature 37.3 C and oxygen saturation 95%. Control chest x-ray in the intensive care unit showed no complication.

Postoperative arterial blood gas, complete blood count and biochemical analysis were found to be in the normal range. She was hemodynamically stable for 3 h but thereafter suddenly hypotension and bradycardia developed and in seconds she hemodynamically collapsed. Cardiopulmonary resuscitation was started immediately. Cardiac rhythm and hemodynamic stability was achieved in 5 min. Soon after, a generalized tonic clonic convulsion was observed lasting for 1 min. Valproic acid therapy and brain computerized tomography (CT) examination was ordered according to the advices of consultant Neurology physician. Bedside echocardiography revealed no bubble, shunt, D-shape or right ventricular dysfunction. Free air was reported in intracranial and extracranial venous structures and in dural venous sinuses most apparent on the posterior side on brain CT by the Radiology consultant (Fig. 2). Thorax CT revealed neither intravascular air nor pulmonary embolism. Carotid sonography displayed no air in the subclavian or jugular veins. Unfortunately we diagnosed pneumocephalus due to cerebral venous air embolism. She clinically deteriorated and despite all effort the case ended up with brain death also documented by cranial CT Angiography.

3. Discussion

Systemic air embolism most commonly arises from traumatic penetrating or blunt disruption of lung or iatrogenic procedures.^{5,6} Lung trauma lacerating lung parenchyma, blood vessels or air passages may cause entrance of air into the pulmonary venous

system. The incidence of systemic air embolism due to severe lung trauma is reported to be 4–14%.⁷

Cerebral venous air embolism is extremely rare and may be easily missed especially in an anesthetized or comatous patient. It was reported that air bubbles can cause cerebral venous embolism by retrograde flow in patients with central venous catheters depending on bubble volume, blood flow velocity, superior vena cava diameter and cardiac output.⁸ Absence or insufficiency of valves in the jugular vein were presumed to be the cause for retrograde embolism.⁹ External cardiac resuscitation was speculated to cause retrograde cerebral venous air embolism due to increased intrathoracic pressure.¹⁰ Heckmann et al reported forced inspiration and hypovolemia as predisposing factors for air embolism in patients with central venous catheters.¹¹

Pneumocephalus usually presents with symptoms including hypotension, bradycardia, coma, hemiparesis and generalized tonic clonic seizures.¹² Upon suspicion, the diagnosis can be easily confirmed by brain CT. Further examination of any intracardiac and intravascular air can be performed by echocardiography and doppler ultrasonography.¹³

Penetrating lung injury or cardiothoracic surgery as in our case are very well known causes of air embolism, but in these cases air entering pulmonary venous system causes systemic air embolism. In our case, according to the report of brain CT by Radiology consultant cerebral venous air embolism in absence of systemic air embolism was remarkable.

As a matter of fact it is not easy to differentiate arterial vs venous embolism in a brain CT but we have to rely on the report of the Radiology Unit. Pneumocephalus was reported to develop due to various etiologies such as thoracic stab wounds, tube thoracostomy, cardiopulmonary resuscitation, injury of the spinal area and neck, central venous catheterization or even in the absence of any air entrance point.^{14–19} Pneumocephalus in our case can not be attributed to a vague cause but could have happened due to several reasons. Unfortunately, a brain CT evaluation could not be done in the ED because of the hemodynamic status of the patient and emergent indication for operation. Therefore according to one scenario; pneumocephalus could have been already present when she arrived to the ED but sedative and neuromuscular blocker agents may have masked the seizures. Postoperatively the gradual increase of embolus size and weaning of the sedatives may have caused clinical symptoms in the patient. Our patient had almost all of the risk factors for the development of pneumocephalus as reported in the literature. The central catheter was in place when the

tonic clonic seizures started which were attributed to pneumocephalus and all the lines were closed and not in touch with air. If central venous catheterization is the cause, the only left mechanism is that air entrance into the central venous system may have occurred during the placement of the catheter. In such a severe trauma where venous access line is of life threatening importance and peripheral venous puncture was impossible due to shock state there seems to be no other alternative than a central venous line but as a selfcriticism in such a case with multiple risk factors for pneumocephalus femoral vein instead of subclavian vein could have been preferred. Nevertheless when subclavian or internal jugular vein is preferred, lying the patient in Trendelenburg position during central venous catheter placement and removal and firm compression for a considerable time period after removal is strictly recommended to avoid this life threatening complication.^{11,12}

In case of a documented cerebral venous embolism hyperbaric oxygen is the mode of treatment strictly recommended to accelerate the dissolution of air bubbles in the circulation and limit the surface of venous infarction.²⁰ Hyperbaric oxygen treatment could not be applied to our patient because this treatment was not applicable in our institute and the patient was hemodynamically not stable for transport.

Pneumocephalus is not a rare complication in patients suffering from especially thoracic and spinal stab wounds and may have catastrophic results. Physicians must be aware of this potential hazardous complication and various etiologies while taking care of patients with multitrauma.

Funding

None.

Conflicts of interest

None declared.

References

- Muth CM, Shank ES. Gas embolism. *N Engl J Med*. 2000;342:476–482.
- Van Hulst RA, Klein J, Lachmann B. Gas embolism: pathophysiology and treatment. *Clin Physiol Funct Imaging*. 2003;23:237–246.
- Pellis e A, Ustrell X, Ruiz V, Guedea A. Retrograde venous cerebral air embolism as a cause of stroke. *Neurologia*. 2012;27:119–121.
- Bothma PA, Schlimp CJ. II. Retrograde cerebral venous gas embolism: are we missing too many cases? *Br J Anaesth*. 2014;112:401–404.
- Campbell PR, Kerridge R. Fatal traumatic air embolism following a stab wound to the chest. *Aust N Z J Surg*. 1993;63:307–309.
- Palmon SC, Moore LE, Lundberg J, Toung T. Venous air embolism: a review. *J Clin Anesth*. 1997;9:251–257.
- Platz E. Tangential gunshot wound to the chest causing venous air embolism: a case report and review. *J Emerg Med*. 2011;41:e25–e29.
- Schlomp CJ, Loimer T, Rieger M, Lederer W, Schmidts MB. The potential of venous air embolism ascending retrograde to the brain. *J Forensic Sci*. 2005;50:906–909.
- Nedelmann M, Pittermann P, Gast KK, et al. Involvement of jugular valve insufficiency in cerebral venous air embolism. *J Neuroimaging*. 2007;17:258–260.
- Imanishi M, Nishimura A, Tabuse H, et al. Intracranial gas on CT after cardiopulmonary resuscitation: 4 cases. *Neuroradiology*. 1998;40:154–157.
- Heckmann JG, Lang CJ, Kindler K, Huk W, Erbguth FJ, Neund rfer B. Neurologic manifestations of cerebral air embolism as a complication of central venous catheterization. *Crit Care Med*. 2000;28:1621–1625.
- Brouns R, De Surgeloose D, Neetens I, et al. Fatal venous cerebral air embolism secondary to a disconnected central venous catheter. *Cerebrovasc Dis*. 2006;21:212–214.
- Tran P, Reed EJ, Hahn F, Lambrecht JE, McClay JC, Omojola MF. Incidence, radiographical features, and proposed mechanism for pneumocephalus from intravenous injection of air. *West J Emerg Med*. 2010;11:180–185.
- Tejirian T, Gabikian P, Petrosyan M, Inaba K, Demetriades D. Pneumocephalus after penetrating thoracic trauma: case report and review of literature. *J Trauma*. 2009;67:E156–E158.
- Malca SA, Roche PH, Touta A, Pellet W. Pneumocephalus after thoracotomy. *Surg Neurol*. 1995;43:398–401.
- Dutra M, Massumoto C. Images in clinical medicine. Cerebral air embolism. *N Engl J Med*. 2012;367:850.
- Halbertsma FJ, Mohns T, Bok LA, Niemarkt HJ, Kramer BW. Prevalence of systemic air-embolism after prolonged cardiopulmonary resuscitation in newborns: a pilot study. *Resuscitation*. 2015;93:96–101.
- Rahamimov N, Mulla H, Freiman S. Cerebrospinal fluid leakage and pneumocephalus secondary to spine stab wounds. *J Orthop Traumatol*. 2010;11:57–59.
- Choi YY, Hyun DK, Park HC, Park CO. Pneumocephalus in the absence of craniofacial skull base fracture. *J Trauma*. 2009;66:E24–E27.
- Moon RE. Hyperbaric oxygen treatment for air or gas embolism. *Undersea Hyperb Med*. 2014;41:159–166.