

HOSTED BY



Contents lists available at ScienceDirect

Turkish Journal of Emergency Medicine

journal homepage: <http://www.elsevier.com/locate/TJEM>

Case report

Importance of back blow maneuvers in a 6 month old patient with sudden upper airway obstruction

Pinar Gencpinar ^{a,*}, Murat Duman ^b^a Akdeniz University, Department of Pediatric Neurology, Antalya, Turkey^b Dokuz Eylul University, Department of Pediatric Emergency Care, Izmir, Turkey

ARTICLE INFO

Article history:

Received 29 June 2013

Received in revised form

15 July 2013

Accepted 7 July 2014

Available online 5 March 2016

Keywords:

Upper airway obstruction

Child

Back blows maneuvers

ABSTRACT

Foreign body aspiration in children under four years old is one of the most frequently observed reasons for accident related deaths. It is more common in this age group due to inadequate swallowing functions and exploration of objects with the mouth. The most frequently encountered foreign bodies are food and toy parts. Life threatening complete laryngeal obstruction is rarely observed. Dyspnea, hypersalivation, cough and cyanosis can be seen. The basic and life-saving treatment approach is complete removal of foreign body maneuvers in the sudden onset of total obstruction. Here we report a six-month old male, who ingested a foreign body and was treated with back blow maneuvers successfully. In this case we emphasized the importance of back blow maneuvers.

Copyright © 2016 The Emergency Medicine Association of Turkey. Production and hosting by Elsevier B.V. on behalf of the Owner. This is an open access article under the CC BY-NC-ND license (<http://creativecommons.org/licenses/by-nc-nd/4.0/>).

1. Introduction

Foreign body aspiration is one of the most frequent reasons of accident related deaths as well as a frequent cause of emergency department admissions. Foreign body aspiration-related deaths account for 5% of deaths under the age of four. The infant age group forms the highest risk group because of the fact that their swallow functions are inadequate and they usually take objects into their mouths to recognize.¹ The most frequently extracted foreign bodies are food and toy parts.² Life threatening laryngeal complete obstruction is rarely observed. Complete obstruction may result in deaths; and partial obstruction may result in atelectasis, emphysema, bronchiectasis, and also rarely deaths.³ Mortality reaches about 40%, especially in foreign bodies in the glottic region. Clinical findings vary depending on the place of obstruction. If upper airways are obstructed, findings such as respiratory distress, increase in oral secretions, cough, and cyanosis can be observed.^{4,5} In unexpected complete obstruction, foreign body retrieval maneuvers are basic and lifesaving treatment approaches.⁶

2. Case

A six-month-old male presented to emergency service with a history of swallowing a key. It was learned from his parents that he took a key, which was found on the ground at home, into his mouth and after that he began coughing. He was immediately brought to the emergency department. On admission, he was agitated and uncomfortable, had cough and could not swallow his secretions. Direct visualization was not performed, because of patient was too small to cooperate, agitated and as well, the use of tongue blade could risk the safety of the airway. Pulmonary sounds were appreciated equally and there was no stridor. There was no cyanosis and saturation was measured as 96%. An otorhinolaryngology consultant was informed because it was thought that an upper airway obstruction may develop and an emergency intervention may be needed. Direct radiography was taken in order to determine the type and the location of the foreign body precisely (Fig. 1a). After a short period of time (in seconds), respiratory distress and stridor developed in the patient. As a result of these findings, it was thought that complete laryngeal obstruction had developed and the back blow maneuver was applied by placing the patient in the prone and upside-down position. The foreign body was expelled with the third strike. All symptoms of the patient regressed (Fig. 1b). The patient was followed in the pediatric emergency care for 4 h due to possibility of a supra-glottic edema development. The

* Corresponding author: Tel.: +90 505 887 92 58.

E-mail address: pinargencpinar@yahoo.com.tr (P. Gencpinar).

Peer review under responsibility of The Emergency Medicine Association of Turkey.

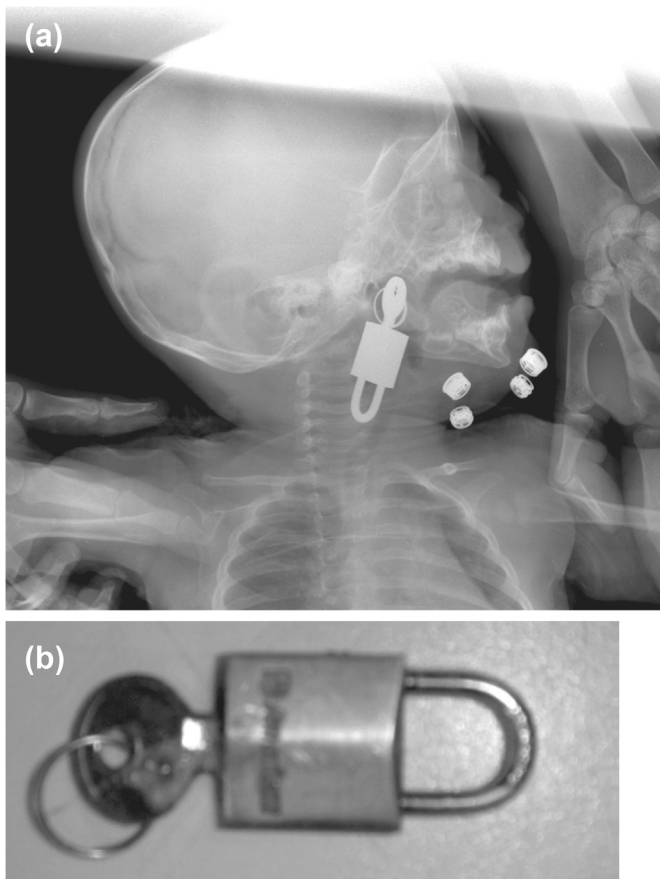


Fig. 1. (a) Direct radiogram of the patient; (b) The foreign body, which was removed back with a back blow maneuver.

patient was discharged from the hospital without any complaints and with normal vital signs.

3. Discussion

Foreign body aspiration is one of the most frequent reasons for emergency department admissions. As in our case, complete laryngeal obstruction rarely occurs but its mortality is high if it is not managed appropriately and promptly.³ The decision of intervention should be based on clinical findings when faced with such a situation. If the patient can cough enough and have respiratory effort, then no intervention is necessary. In this case, the best approach is to calm and to move the patient as little as possible.⁶ Direct radiographies of airways or chest are helpful in terms of type and location of the foreign body, if the patient's condition is not critical.⁷ It should be kept in mind that only metallic foreign

bodies can be directly visualized on direct films. The X-ray of our patient showed that the padlock and its key were present in the epiglottic region. Upon admission of our patient, there was no stridor, no respiratory distress and a strong cough reflex. However, if the cough reflexes are not strong enough, or cyanosis is developing, the best approach is to try to remove the foreign body as quickly as possible.

If the foreign body is visualized, manual removal can be tried. If the foreign body is not visible, back blows and chest compression maneuvers are the most suitable treatment methods, especially in this age group. In this maneuver, the rescuer sits down and rests his forearm on his thigh. The infant is held prone and facedown on the rescuer's forearm. The infant's head should be supported by holding the jaw tightly. The rescuer delivers up to five sharp blows with the heel of his hand to the inter-scapular area. Effective and powerful application of this maneuver increases the likelihood of a successful intervention.⁶ If the foreign body cannot be removed by these maneuvers, removal by using Magill forceps must be tried. Percutaneous transtracheal ventilation with needle cricothyrotomy may be necessary for foreign bodies above the level of vocal cord. For the foreign bodies below the level of vocal cord, pushing the foreign body into the right main bronchus and restoring the ventilation by the left lung may be a necessary procedure.⁸ All the necessary interventions should be performed by collaboration of an experienced team.⁹ The back blow maneuver was used due to the development of stridor and cyanosis in follow-up of our case and the foreign body was removed after the third blow in our case.

As a result, we wanted to underline once again through this case the lifesaving effect of rapid and effective application of foreign body retrieval maneuvers in cases where a foreign body related complete obstruction develops in the airway.

References

1. Hammer J. Acquired upper airway obstruction. *Paediatr Respir Rev.* 2004;5: 25–33.
2. Lima JAB, Fischer GB. Foreign body aspiration in children. *Pediatr Respir Rev.* 2002;3:303–307.
3. Gregori D, Salerni L, Scarinze C, et al, The ESFBI Study Group. Foreign bodies in the upper airways causing complications and requiring hospitalization in children aged 0–14 years: results from the ESFBI study. *Eur Arch Otorhinolaryngol.* 2008;265:971–978.
4. Eren S, Balci AE, Dikici B, Doblun M, Eren MN. Foreign body aspiration in children: experience of 1160 cases. *Ann Trop Paediatr.* 2003;23:31–37.
5. Robinson P. Laryngeal foreign bodies in children: first stop before the right main bronchus. *J Paediatr Child Health.* 2003;49:477–479.
6. Berg MD, Schexnayder SM, Chameides L, et al, American Heart Association. Pediatric basic life support: 2010 American heart association guidelines for cardiopulmonary resuscitation and emergency cardiovascular care. *Pediatrics.* 2010;126:e1345–e1360.
7. Mu LC, Sun DQ, He P. Radiological diagnosis of aspirated foreign bodies in children: review of 343 cases. *J Laryngol Otol.* 1990;104:778–782.
8. Pflieger A, Eber E. Management of acute severe upper airway obstruction in children. *Paediatr Respir Rev.* 2013;14:70–77.
9. Zur KB, Litman RS. Pediatric airway foreign body retrieval: surgical and anesthetic perspectives. *Paediatr Anaesth.* 2009;19:109–117.