



## Visual diagnosis

## Acute pelvic pain in female with ruptured ectopic pregnancy: Magnetic Resonance Imaging as problem solving tool



Venkatraman Indiran\*

Department of Radiodiagnosis, Sree Balaji Medical College and Hospital, Chennai, Tamil Nadu, India

## ARTICLE INFO

## Article history:

Received 29 November 2014

Received in revised form

25 December 2014

Accepted 5 January 2015

Available online 8 May 2016

A 31 year old female was referred to our Magnetic Resonance Imaging (MRI) department with history of lower abdominal pain for three days. The patient had a history of irregular periods, with no definite period of amenorrhea. There was no history of bleeding per vagina. The ultrasound performed by the referring physician showed a complex right adnexal lesion abutting the uterus with no free fluid in the pelvis, prompting the physician to think of a broad ligament fibroid. Subsequently the patient tested mildly positive for urine gravindex. As the physician felt that ultrasound was not contributing to a proper diagnosis, MRI pelvis was requested to help solve the clinical problem. Blood sample was given for assessment of Serum human chorionic gonadotropin (beta hCG) level at this same time. MRI images are shown as Figs. 1–4.

### 1. Diagnosis: ruptured ectopic pregnancy

MRI of the pelvis revealed a tubular structure with T2 hypointense fluid level measuring  $\sim 4.1 \times 2.3 \times 4.1$  cm in the right adnexal region, medial to the right ovary (Fig. 1). There was an ovoid T2 and GRE hypointense signal lesion with T2 hyperintense center within the tubular lesion (Fig. 2). There was a T1 hyperintense signal around the right adnexal lesion (Fig. 3). Free fluid with T1 intermediate signal and T2 hypointense signal was also seen in the pelvis (Fig. 4). Uterine endometrial thickness measured  $\sim 9.7$  mm with no intrauterine gestational sac. Right hematosalpinx

with ectopic tubal gestation along with rupture, peritubal hematoma and hemoperitoneum was considered and the referring clinician was alerted. The patient was taken for laparotomy without waiting for the serum beta hCG level. About 500 ml of intraperitoneal blood was noted. Tubectomy was performed for the ruptured right fallopian tube gestation. Serum beta hCG level turned out to be 7356 IU/ml. The patient recovered well following the surgery.

Ectopic pregnancy, an important cause of morbidity and mortality in the first trimester, does not always present classically with the triad of abdominal pain, bleeding per vagina and adnexal lesion. Prompt diagnosis helps in alleviating the morbidity and avoiding mortality. Though ultrasound is the primary modality for diagnosing ectopic pregnancy, MRI of the pelvis has a definite role as a problem solving tool.<sup>1</sup> Though more than 90% of ectopic pregnancies are visualized on transvaginal ultrasound, false

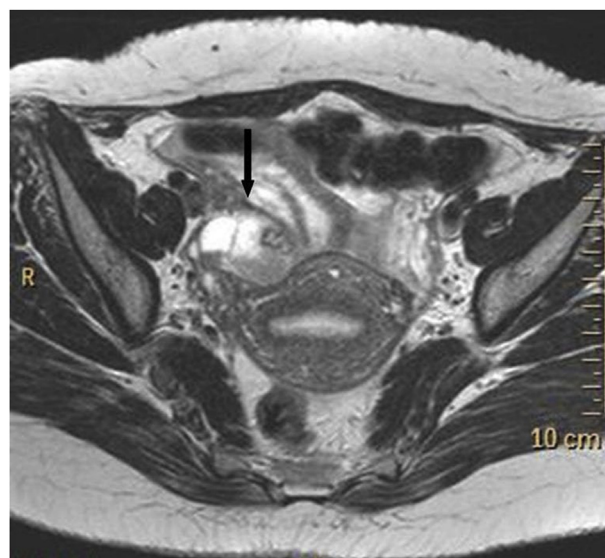
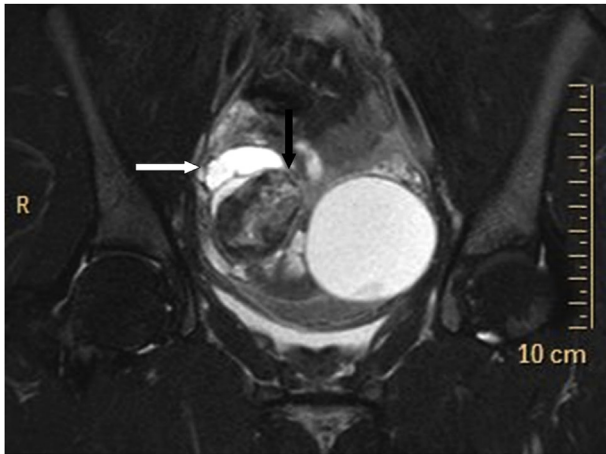


Fig. 1. Axial T2-weighted image demonstrates a hypointense fluid level in the tubular structure, representing hemorrhage in the right fallopian tube (black arrow).

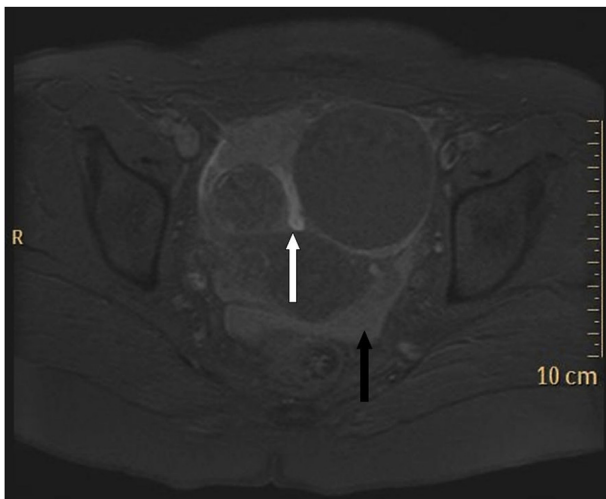
\* 32 Kumarapuram, Chromepet, Chennai, Tamil Nadu 600044, India. Tel.: +91 04422653429 (landline), +91 9443067358 (mobile).

E-mail address: [ivraman31@gmail.com](mailto:ivraman31@gmail.com).

Peer review under responsibility of The Emergency Medicine Association of Turkey.



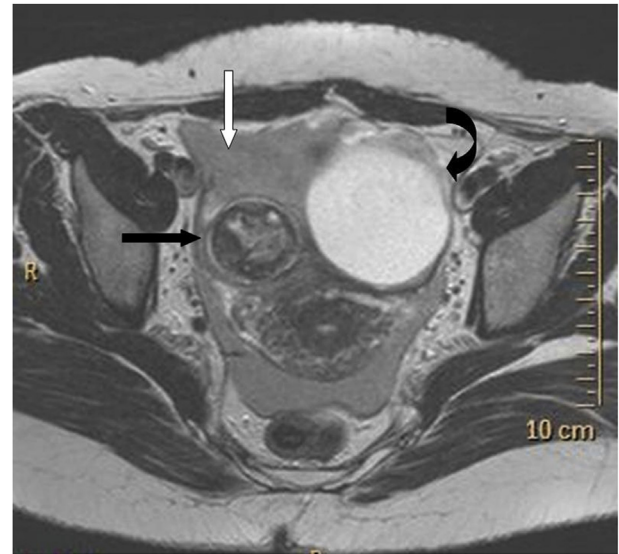
**Fig. 2.** Coronal fat saturated T2-weighted image reveals increased signal intensity in the center (black arrow) and decreased signal intensity in the peripheral (white arrow) part of the right adnexal lesion.



**Fig. 3.** Axial fat saturated T1-weighted image demonstrates a hyperintense signal (white arrow) medial to the right adnexal lesion and free fluid in the pelvis with intermediate signal intensity, representing hemorrhagic content.

positive diagnoses account for about 5–6%.<sup>2</sup> Corpus luteum, bowel, paratubal cyst, hydrosalpinx, endometrioma and fibroid account for the false positive diagnoses of ectopic pregnancy.<sup>3</sup>

The classic findings of ectopic pregnancy on MRI are lack of intrauterine pregnancy, hemoperitoneum, tubal mass, hematosalpinx and wall enhancement of the dilated fallopian tube.<sup>4,5</sup> The presence of hematosalpinx in a woman with a positive pregnancy test and with no intrauterine gestational sac is highly



**Fig. 4.** Axial T2 weighted image shows a T2 hypointense signal lesion with T2 hyperintense center in the right adnexal region (black arrow), and a T2 hypointense signal free fluid in the pelvis (white arrow). Incidental left ovarian cyst was found in the left adnexal region (curved black arrow).

concerning for ectopic pregnancy, even in the absence of a clearly identifiable extra-uterine gestational sac.<sup>5</sup> The inclusion of a T1-weighted pulse sequence is helpful in identifying blood products and is recommended as part of imaging protocol for pregnant patients.<sup>5</sup> Mimics of ectopic pregnancy include corpus luteal cyst and ovarian masses. Differentials for hemoperitoneum include placental abnormalities like placenta accreta and percreta.<sup>5</sup>

It is imperative that the radiologists, obstetricians and emergency physicians be familiar with these features and always consider the possibility of ectopic pregnancy in the setting of hemoperitoneum or a pelvic mass in a woman of child-bearing age.<sup>1</sup>

## References

1. Kao LY, Scheinfeld MH, Chernyak V, Rozenblit AM, Oh S, Dym RJ. Beyond ultrasound: CT and MRI of ectopic pregnancy. *AJR Am J Roentgenol.* 2014;202:904–911.
2. Condous G, Okaro E, Khalid A, et al. The accuracy of transvaginal ultrasonography for the diagnosis of ectopic pregnancy prior to surgery. *Hum Reprod.* 2005;20:1404–1409.
3. Sivalingam VN, Duncan WC, Kirk E, Shephard LA, Horne AW. Diagnosis and management of ectopic pregnancy. *J Fam Plann Reprod Health Care.* 2011;37:231–240.
4. Kataoka ML, Togashi K, Kobayashi H, Inoue T, Fujii S, Konishi J. Evaluation of ectopic pregnancy by magnetic resonance imaging. *Hum Reprod.* 1999;14:2644–2650.
5. Parker 3rd RA, Yano M, Tai AW, Friedman M, Narra VR, Menias CO. MR imaging findings of ectopic pregnancy: a pictorial review. *Radiographics.* 2012;32:1445–1462.