

Retropharyngeal Hematoma due to Oral Warfarin Usage

Oral Varfarin Kullanımına Bağlı Gelişen Retrofarengeal Hematom

Ibrahim TOKER, Ozge DUMAN ATILLA, Murat YESILARAS, Burcu URSAVAS

Department of Emergency Medicine, Tepecik Training and Research Hospital, Izmir

SUMMARY

Retropharyngeal hematoma due to anticoagulant usage is a rare, life-threatening situation which must be immediately diagnosed and treated. Immediate control of the airway and coagulopathy are the bases of treatment management. Patients often respond to conservative treatment but occasionally urgent tracheostomy and endotracheal intubation may be necessary. We presented a case of retropharyngeal hematoma secondary to warfarin usage in a 49-year-old male.

Key words: Emergency department; retropharyngeal hematoma; warfarin overdose.

ÖZET

Antikoagülan kullanımına bağlı retrofarengeal hematom nadir görülür, hızlı tanı ve tedavi edilmesi gereken hayatı tehdit edici bir durumdur. Hava yolu ve koagülopatinin acil kontrolü tedavi yönetiminin esasını oluşturur. Olgular çoğunlukla konservatif tedaviye cevap verirken bazen endotrakeal entübasyon ve acil trakeotomi gerekebilir. Bu yazıda, varfarin kullanımına sekonder retrofarengeal hematom gelişmiş 49 yaşındaki erkek olguyu sunduk.

Anahtar sözcükler: Acil servis; retrofarengeal hematom; varfarin aşırı dozu.

Introduction

Warfarin and other vitamin K antagonists are used in a variety of clinical situations.^[1] By inhibiting vitamin K cyclo-oxygenase reductase and vitamin K reductase enzymes that play a role in α (alpha) carboxylation of factor 2, factor 7, factor 9, factor 10 and other vitamin K related proteins, warfarin prevents the activation of coagulation factors and thus reduces coagulation or inhibits it entirely.^[2] Its most frequent side-effect is hemorrhage. Spontaneous hemorrhage as a result of anticoagulation with warfarin is rare, potentially life-threatening and requires individual care for each patient.^[3,4]

In this article, we present a case with retropharyngeal hematoma due to warfarin overdose.

Case Report

A 49-year-old male with ongoing sore throat for two days presented to our emergency department (ED). The patient,

who had had a previous history of mitral valve replacement and oral warfarin usage, was complaining of swallowing difficulty, hoarseness and oral intake disorder. On admission, the patient had a blood pressure of 116/67 mmHg, heart rate of 106/min, temperature of 36.6 °C, peripheral O₂ saturation of 97% and respiratory rate of 22/min. Bilateral neck swelling, a few petechia in soft palate and common ecchymosis and edema in pharynx were detected in the physical examination (Figure 1). Except for metallic valve sound, cardiovascular system examination was normal. The patient's laboratory tests showed activate Partial Thromboplastin Time (aPTT) 81.1 secs, Prothrombin Time (PT) 183 secs, International Normalized Ratio (INR) 15.9, hemoglobin (Hb) 4.9 gr/dL, creatinine 1.6 mg/dL and no electrolyte imbalance, leucocytosis or thrombocytopenia. After administration of 10 mg intravenous vitamin K, 3 units of fresh frozen plasma and 5 units of packed red blood cells to the patient in the emergency department, INR and Hb were detected at 1.23

Submitted: January 13, 2013 **Accepted:** February 21, 2014 **Published online:** November 30, 2014

Correspondence: Dr. Ibrahim Toker. Izmir Tepecik Eğitim ve Araştırma Hastanesi, Acil Tıp Kliniği, Gaziler Caddesi, No: 468, Yenisehir, 35170 İzmir, Turkey.

e-mail: ibrahimtoker9@gmail.com



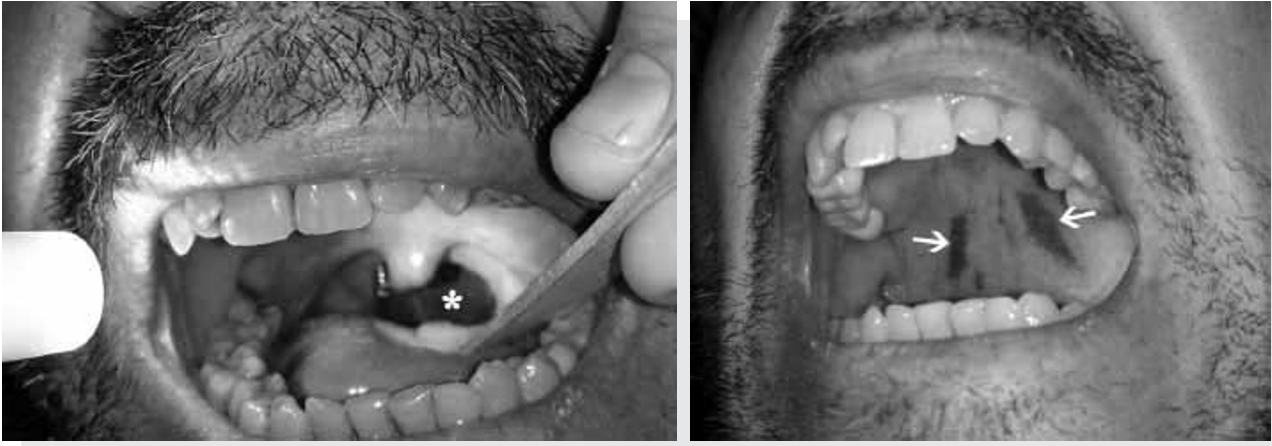

Figure 1. Bilateral neck swelling, a few petechia in soft palate and widespread ecchymosis and edema in pharynx.

and 9.59 g/dl, respectively. In the lateral cervical graphy, pre-vertebral soft tissue thickness at level C2 was measured at 33.5 mm (Figure 2). Noncontrast enhanced computerized tomography (CT) of the neck was performed and revealed retropharyngeal hematoma spread through to subglottic area from nasopharynx (Figure 2).

The patient consulted with internal medicine specialist and otorhinolaryngologist and was admitted to the otorhinolaryngology clinic for follow-up. The patient was discharged following the regression of pharyngeal hematoma and absence of additional problems during his hospital stay.

Discussion

Anticoagulants are commonly used for the treatment and inhibition of arterial and venous thrombosis and thrombosis due to heart valve prostheses.^[5] Their usage is troublesome because of the narrowness of therapeutic range and changes in metabolism due to genetic factors, drug interaction and nutrition.^[11] Most of the hemorrhage cases that cause obstruction in upper airways due to anticoagulant treatment are retropharyngeal, sublingual or, rarely laryngeal hematomas.^[6] Hematomas in the pharynx area may constitute different clinical cases depending upon their mass and development

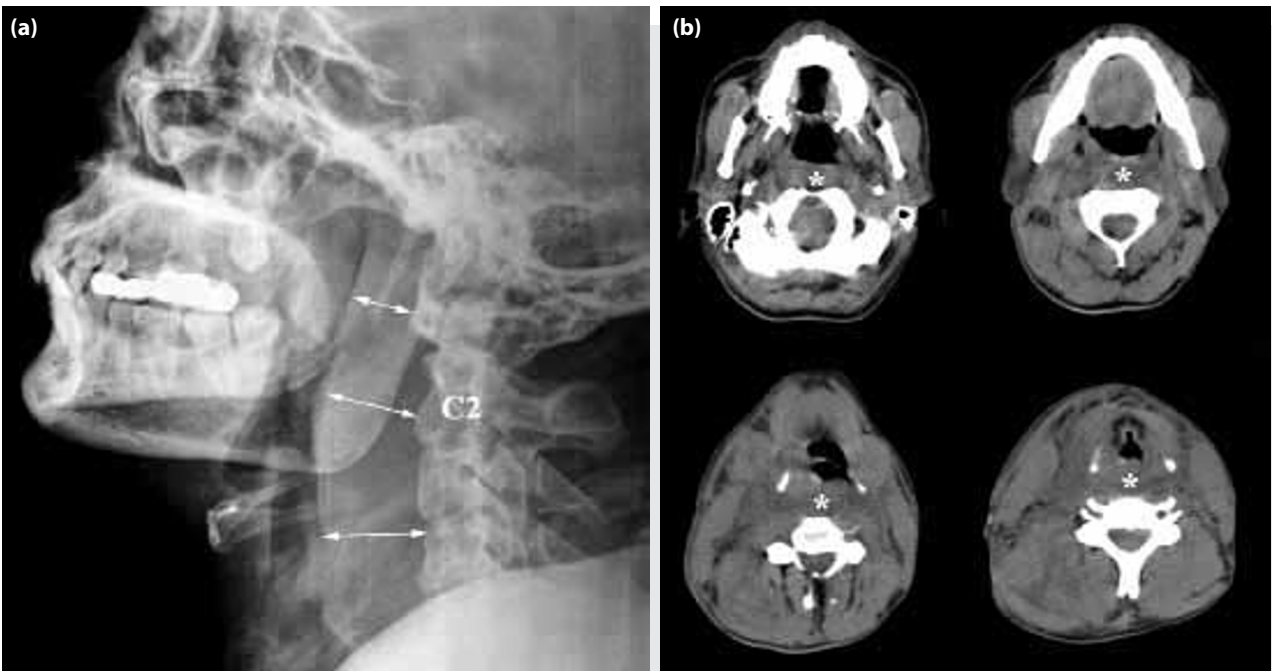


Figure 2. (a) Lateral cervical radiography image. (b) Noncontrast enhanced computerized tomography images of the patient.

speed. Although tenderness and swelling in the neck directly points to this diagnosis, symptoms such as sore throat, shortness of breath, dysphagia, or odinophagia may also point to the same diagnosis.^[7] Some cases have reported warfarin-associated upper airway hemorrhage following a severe coughing episode or straining.⁶ Risk of warfarin-associated major hemorrhage significantly increases when INR value becomes >5.08. Anticoagulation must be inhibited with fresh frozen plasma (FFP) or 2.5-5.0 mg intravenous vitamin K in hemorrhages which are thought to be more serious than the risk of thrombosis and cannot be controlled locally.^[8] There is no information that indicates thromboembolism risk due to temporary reversion of anticoagulation is more dominant than the results of severe hemorrhage in patients with mechanical prosthesis.^[9] Treatment involves providing a secure airway, controlling hemorrhage and correcting coagulopathy. Endotracheal intubation, cricothyroidotomy or tracheostomy may be required depending on the patient's condition.^[10] Most patients with retropharyngeal hematoma can be treated conservatively. Hematoma is mostly cured with conservative treatment, but it might take a few weeks.^[11]

Retropharyngeal hematoma is a life-threatening complication of anticoagulant treatment. Patients might be admitted with complains such as a sore throat, as in our case. These symptoms might be related to common causes such as upper airway infections, so hematoma might be overlooked. Therefore, hematoma in the pharyngeal area should be considered in admitted patients administered anticoagulants and in whom symptoms such as odinophagia, dysphagia, cough and hoarseness are observed.

Conflict of Interest

The authors declare that there is no potential conflicts of interest.

References

1. <http://www.uptodate.com/contents/therapeutic-use-of-warfarin-and-other-vitamin-k-antagonists>, last access: December 18, 2013.
2. Horton JD, Bushwick BM. Warfarin therapy: evolving strategies in anticoagulation. *Am Fam Physician* 1999;59:635-46.
3. Howard MR, Hamilton PJ. Anticoagulation and thrombolytic therapy. In: Howard MR, Hamilton PJ, editors. *Haematology & An Illustrated Colour Text*. 4th ed. UK: Churchill Livingstone; 2013. p. 80-1.
4. Koch CA, Olsen SM, Saleh AM, Orvidas LJ. Spontaneous epiglottic hematoma secondary to supratherapeutic anticoagulation. *Int J Otolaryngol* 2010;2010:201806. [CrossRef](#)
5. Warkentin TE, Crowther MA. Anticoagulant and thrombolytic therapy. In: Young NS, Gerson SL, High KA, editors. *Clinical hematology*. 1st ed. St. Louis; Mosby-Elsevier; 2006. p. 1114-33.
6. Kaya M, Ceylan M, Nesteren S, Yıldırım Ö, Eskiçırak HE, Kadioğulları AN. Pharynx hematoma due to anticoagulant treatment: case report. *Turk J Anesth Reanim* 2012;40:287-9.
7. Aslan S, Keşkek Ö, Kesici A. Spontaneous, retro- and parapharyngeal hematoma due to anticoagulant treatment: case Report. *Turkish Otolaryngology Archive* 2009;47:53-7.
8. <http://www.uptodate.com/contents/antithrombotic-therapy-in-patients-with-prosthetic-heart-valves>, last access: December 12, 2013.
9. Vahanian A, Alfieri O, Andreotti F, Antunes MJ, Baron-Esquivias G, Baumgartner H, et al. European Society of Cardiology (ESC) cardiac valve diseases treatment guide, 2012 version, Turkish Cardiology Association 2012:83-128.
10. Yaman H, Guven DG, Kandis H, Subasi B, Alkan N, Yılmaz S. Sublingual and supraglottic haemorrhage as a complication of warfarin therapy warfarin: case report. *Hong Kong J Emerg Med* 2011;18:177-81.