

Pediatric Acute External Laryngeal Trauma: A Case Report

Pediatric akut eksternal larengeal travma: Olgu sunumu

Türkiye Acil Tıp Dergisi - Turk J Emerg Med 2007;7(1):36-39

Yusuf VAYISOĞLU, Kemal GÖRÜR, Cengiz ÖZCAN, Derya Ü. TALAS, Haktan E. BAĞIŞ

Department of Otorhinolaryngology,
Medicine Faculty of Mersin University, Mersin

SUMMARY

Pediatric external laryngeal trauma is a rare but clinically important injury. In this case, we report a 12-years-old boy who had acute external penetrating laryngeal trauma. Primary signs and symptoms of the patient were hoarseness, respiratory distress and penetrating injury to the anterior neck. The patient underwent immediately tracheostomy and surgical exploration. On long-term follow-up, his voice and airway patency were improved. This case suggests the importance of early recognition, careful evaluation of acute external laryngeal trauma and immediately restoration of laryngeal skeletal framework for preserved vocal and airway protecting functions of larynx.

Key words: Laryngeal trauma; pediatric; penetrating trauma.

ÖZET

Pediatric akut eksternal larengeal travmalar nadir görülen ancak önemli travmalardır. Bu yazıda akut eksternal larengeal travmaya uğrayan 12 yaşında erkek çocuğu sunuldu. Primer yakınma ve bulguları, ses kısıklığı, solunum sıkıntısı ve boyun ön bölümde penetran yara idi. Hastaya acil olarak trakeotomi ve boyun eksplorasyonu uygulandı. Uzun dönem takipte hastanın konuşma ve solunum sorunu düzeldi. Bu olgu larenksin konuşma ve hava yolu fonksiyonlarını korumak için; akut eksternal larengeal travmanın erken tanısı ve acil olarak larengeal çatı tamirinin önemini göstermektedir.

Anahtar sözcükler: Larengeal travma; pediatrik; penetran travma.

Correspondence (İletişim)

Yusuf VAYISOĞLU, M.D.

Department of Otorhinolaryngology,
Medicine Faculty of Mersin University,
33100 Mersin, Turkey
Tel: +90 - 324 - 337 43 00
Fax (Faks): +90 - 324 - 337 43 05
e-mail (e-posta): yvayisoglu@gmail.com

Introduction

External laryngeal trauma is a rare but a potentially lethal injury. External laryngeal trauma comprises less than 1% of all trauma cases. The pediatric larynx is located high in the neck, protected by mandible, and its cartilage is relatively soft and pliable. Thus, incidence of laryngeal injury is occurred lower than adults. The incidence of laryngeal trauma among children is generally low. However, the loose attachment of the submucosal tissue to the underlying perichondrium and the immature intercartilaginous connections make mucosal injury and complete laryngotracheal disruption more likely.^[1,2] In generally, blunt trauma is more common than penetrating trauma. Blunt trauma is most often due to motor vehicle accident, sports injuries and strangulation type injuries. Penetrating trauma is most often due to gunshot or knife wounds.^[3] Management of laryngeal trauma must begin with maintaining the airway patency. Orotracheal intubation is hazardous in laryngeal trauma particularly in blunt trauma, because it's due to extending damage or losing the airway. Tracheostomy is the preferred technique for airway control in blunt laryngeal trauma. However orotracheal intubation appears to be safe for penetrating laryngeal trauma. Management of laryngeal trauma is aimed at restoring the skeletal framework and the epithelial lining of the larynx. Thus preserve its vocal, respiratory and airway protecting functions.^[4,5]

The purpose of this case report is to define the importance of early recognition, careful evaluation and immediately management of external laryngeal trauma for preserved vocal and airway protecting functions of larynx.

Case Report

A 12-years-old boy was admitted to the emergency room with a history of gunshot injury to the anterior region of the neck. The complaints of patient included hoarseness and moderate dyspnea. The vital signs of the patient were normal, and the patient was alert and conscious. On initial examination there was deep skin wound, burned tissues with gunpowder in anterior region of the neck. The evaluation of the skin laceration revealed hypopharynx and laryngeal structures through the wound.

After confirming the absence of cervical fractures by anterior-posterior and lateral servical X-rays, the patient was taken immediately to the operating room and he was carefully intubated under the general anesthesia. A tracheostomy was performed between the third and fourth tracheal rings and no.5 endotracheal tube was inserted and general anesthesia was given. Then neck exploration was performed. A vertical frag-

mented fracture was observed on the right and left ala of thyroid cartilages. Fracture line was extending through posterior region of cricoid cartilage. The petiol of epiglottis was separated from the anterior commissure with intact aryepiglottic folds. The mucosal cover of the left arytenoids cartilage was lacerated and the left arytenoids cartilage displaced posteriorly. The mucosa of the vocal cords was lacerated. The fractures lines were illustrated in Fig. 1. After the epiglottis reposed, hypopharyngeal and laryngeal mucosal lacerations were sutured with 4/0 vicryl®. Left arytenoids cartilage reposed before the suturation of mucosal laceration. Fractures of cartilages were repaired and sutured with 3/0 vicryl®. After the nasogastric tube insertion, the burned edge of wound excised and closed with using 3/0 catgut, 4/0 silk (Fig. 1). After the suturation, tracheotomy tube with cuff was inserted to the tracheotomy.

Postoperatively, the patient received prophylactic intravenous broad spectrum antibiotic therapy and intravenous corticosteroid therapy. Antacids and H2-blockers were given to prevent laryngopharyngeal reflux. Because reflux may cause mucosal injuries of laryngeal tissues. Oral food intake was begun on the postoperative third day, tracheotomy tube was plugged on the seventh day and decannulated in the following day. All laryngeal and hypopharyngeal structures were observed as normal except the right vocal cord paresis at the postoperative first month and mild disphonia were noted. The granulation tissue was observed in the anterior commissure at the postoperative third month and this tissue was totally excised by microlaryngoscopic surgery. All laryngeal structures and bilateral vocal cord movements were observed as normal at the postoperative first week.

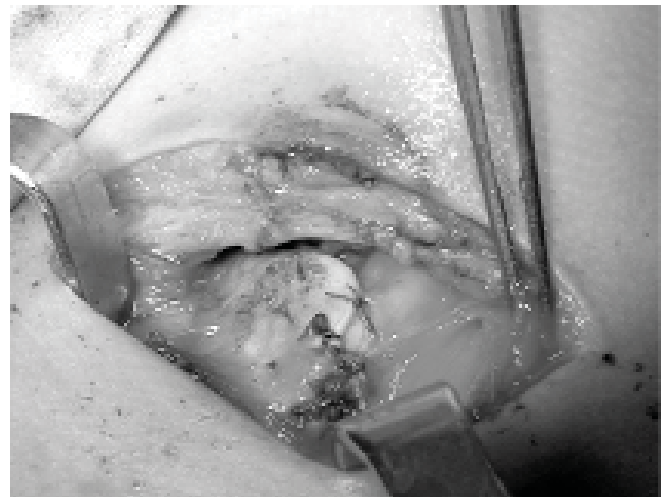


Fig. 1. This picture shows the fracture line after repairing.

Discussion

The most common symptoms after external laryngeal trauma are dysphonia, dyspnea, odynophagia, hemoptysis and pain over the larynx. Classic findings on physical examination include disruption of anatomic landmarks such as loss of the laryngeal prominence or a grossly displaced fracture of the laryngeal skeleton, laryngeal tenderness, subcutaneous emphysema and stridor.^[1,4,5] Laryngeal trauma can be divided into two main groups which are external trauma and internal trauma. External laryngeal trauma can be categorized as blunt trauma, penetrating trauma and iatrogenic trauma (tracheostomy and birth delivery injuries). Internal laryngeal trauma include iatrogenic (intubation, laryngoscopy), thermal (burn inhalation injury), chemical (gastro-esophageal reflux disease and caustic ingestion) and mechanical (foreign body, voice abuse).^[6] The estimated laryngeal injury is 1:15000 to 1:43000 visits to emergency rooms.^[7,8] Laryngeal trauma is rarely encountered but it is potentially lethal. It has a mortality rate of approximately 40% for blunt trauma and 20% for penetrating trauma.^[9] Jewett et al. found a lower incidence of acute laryngeal trauma (1 in 137000 patient admissions) and estimated a lower mortality rate than previous studies (2%). Their series shows that one third of the patients required tracheostomy. Patients requiring tracheostomy had a higher mortality rate.^[10]

Penetrating trauma may involve multiple vital structures such as the esophagus or the carotid neurovascular bundle. A diagnosis of upper aerodigestive tract injury is suggested by the presence of cervical subcutaneous emphysema or crepitation.^[11] The appearance of an immobile vocal cord in a post-traumatic patient with laryngeal injury in the first line indicates inferior laryngeal nerve paresis or arytenoid subluxation in the differential diagnosis.^[12] In our case, left vocal cord paralysis was observed postoperatively. There was no arytenoid subluxation.

Immediate airway management is one of the most controversial aspects of acute laryngotracheal trauma. Some authors preferred that oral intubation is a safe and effective way of securing an airway. Other authors claim that tracheotomy using local anesthesia is the appropriate method for securing an airway. They argue that intubation is difficult in this setting due to the extending damage to the internal laryngeal structures or losing the airway.^[1] Tracheotomy is more difficult procedure in a child than in an adult, and cooperation of a child for this procedure using local anesthesia is unlikely. Therefore, the pediatric airway should be secured in the operating room after induction of general anesthesia with inhalation agents.^[13] Cricothyroidotomy should be avoided in sus-

pected laryngeal trauma, especially in children. Because of our case was uncooperated and there was an airway defect in superior of the laryngotracheal region, patient was firstly intubated and then tracheotomy was performed. After the endotracheal tube replaced to the tracheotomy region, laryngotracheal defect was repaired.

Laryngeal mucosal lacerations from penetrating trauma should be repaired early (within 24 hours). The time elapsed before repair has an effect on both airway stenosis and on voice.^[3] The early repair of exposed cartilage prevents chondritis. Early intervention in laryngeal trauma will minimize the development of infection, granulation tissue and scar formation.^[6] Our patient underwent an early surgical intervention, and his voice quality and airway patency was satisfactory.

The surgical repair of laryngeal fractures involved using sutures, stainless steel wire, plate fixation or grafting with autologous cartilage.^[14,15] In our case, we used polyglactin 910 (Vicryl) sutures for stabilization of cartilaginous framework.

The cricoid is the particularly important part of the laryngeal skeleton. It is the only complete ring in the respiratory tract. If the cricoid is disrupted, stenosis would occur in the respiratory tract. The indications for stenting in laryngeal injuries are controversial. The stent helps to support the laryngeal framework and prevent adhesions within the larynx. However, stents are associated with increased inflammation and granulation which can cause narrowing of the airway. In the presence of severe soft tissue disruption or lacerations involving the anterior commissure, stents may help preventing synechiae.^[16]

Our patient had symptoms of hoarseness and mild airway distress. No CT scan was taken for the evaluation of the laryngeal region because of the mucosal laceration and laryngeal injury could be seen through wound. Some authors recommend CT in selected cases in order to assess the extend damage to the laryngeal framework, especially in cases of blunt laryngeal trauma.^[17,18] Gold et al. reported that the CT scan is reserved for patients when the injury is suspected due to history and clinical examination with no obvious indications for surgical intervention.^[1]

Laryngeal trauma is relatively rare but can be lethal. The main functions of the larynx are airway and phonation. In laryngeal trauma, the skeletal framework and the epithelial lining must be intact to maintain these functions. Laryngeal mucosal lacerations and laryngeal skeletal fracture due to penetrating trauma should be repaired early. This preserves vocal and airway protecting functions of larynx.

References

1. Gold SM, Gerber ME, Shott SR, Myer CM. Blunt laryngotracheal trauma in children. *Arch Otolaryngol Head Neck Surg* 1997;123:83-7.
2. Merritt RM, Bent JP, Porubsky ES. Acute laryngeal trauma in the pediatric patient. *Ann Otol Rhinol Laryngol* 1998;107:104-6.
3. Butler AP, Wood BP, O'Rourke AK, Porubsky ES. Acute external laryngeal trauma: experience with 112 patients. *Ann Otol Rhinol Laryngol* 2005;114:361-8.
4. Thevasagayam MS, Pracy P. Laryngeal trauma: a systematic approach to management. *Trauma* 2005;7:87-94.
5. Shockley WW, Ball SS. Laryngeal trauma. *Curr Opin Otolaryngol Head Neck Surg* 2000;8:497-502.
6. Myer CM. Trauma of the larynx and craniofacial structures: airway implications. *Paediatr Anaesth* 2004;14:103-6.
7. Schaefer SD. The acute management of external laryngeal trauma. A 27-year experience. *Arch Otolaryngol Head Neck Surg* 1992;118:598-604.
8. Gussack GS, Jurkovich GJ, Luterman A. Laryngotracheal trauma: a protocol approach to a rare injury. *Laryngoscope* 1986;96:660-5.
9. Vassiliu P, Baker J, Henderson S, Alo K, Velmahos G, Demetriades D. Aerodigestive injuries of the neck. *Am Surg* 2001;67:75-9.
10. Jewett BS, Shockley WW, Rutledge R. External laryngeal trauma analysis of 392 patients. *Arch Otolaryngol Head Neck Surg* 1999;125:877-80.
11. Goudy SL, Miller FB, Bumpous JM. Neck crepitation: evaluation and management of suspected upper aerodigestive tract injury. *Laryngoscope* 2002;112:791-5.
12. Schroeder U, Motzko M, Wittekindt C, Eckel HE. Hoarseness after laryngeal blunt trauma: a differential diagnosis between an injury to the external branch of the superior laryngeal nerve and an arytenoid subluxation. A case report and literature review. *Eur Arch Otorhinolaryngol* 2003;260:304-7.
13. O'Connor PJ, Russell JD, Moriarty DC. Anesthetic implications of laryngeal trauma. *Anesth Analg* 1998;87:1283-4.
14. de Mello-Filho FV, Carrau RL. The management of laryngeal fractures using internal fixation. *Laryngoscope* 2000;110:2143-6.
15. Thekdi A, Carrau RL. Fixation techniques in laryngeal trauma. *Operative Techniques in Otolaryngology Head and Neck Surgery* 2002;13:277-80.
16. Hwang SY, Yeak SC. Management dilemmas in laryngeal trauma. *J Laryngol Otol* 2004;118:325-8.
17. Fuhrman GM, Stieg FH, Buerk CA. Blunt laryngeal trauma: classification and management protocol. *J Trauma* 1990;30:87-92.
18. Angood PB, Attia EL, Brown RA, Mulder DS. Extrinsic civilian trauma to the larynx and cervical trachea-important predictors of long-term morbidity. *J Trauma* 1986;26:869-73.