

HOSTED BY



ELSEVIER

Contents lists available at ScienceDirect

# Turkish Journal of Emergency Medicine

journal homepage: <http://www.elsevier.com/locate/TJEM>

## Traumatic pseudocyst due to blunt trauma: Case report



Sinan Becel, Beliz Oztok, Gulhan Kurtoglu Celik, Ferhat Icme, Alp Sener,  
Gul Pamukcu Gunaydin\*

Department of Emergency Medicine, Ankara Atatürk Training and Research Hospital, Ankara, Turkey

### ARTICLE INFO

#### Article history:

Received 23 August 2013

Received in revised form

22 October 2013

Accepted 7 February 2014

Available online 30 December 2015

#### Keywords:

Blunt chest injury

Traumatic pseudocyst

### ABSTRACT

Damage to lung parenchyma due to blunt thoracic trauma often appears as contusion or hematoma. Cavitory lung lesions or pseudocyst formation due to trauma is a rare phenomenon. In the literature traumatic pseudocysts are also known as pseudocystic hematomas, traumatic lung cavity and traumatic pneumotocel. Traumatic pseudocysts usually have good clinical prognosis, recover spontaneously with supportive treatment and do not require surgery. In this article, we present the case of 52 year old male who was brought to the emergency department after a fall from height and was diagnosed with lung contusions and traumatic cyst.

Copyright © 2015 The Emergency Medicine Association of Turkey. Production and hosting by Elsevier B.V. on behalf of the Owner. This is an open access article under the CC BY-NC-ND license (<http://creativecommons.org/licenses/by-nc-nd/4.0/>).

### 1. Introduction

Lung injury following blunt chest trauma may appear in various clinical forms such as contusion and laceration. Self-limiting cavitory lesions in the lung parenchyma after trauma are rarely seen and are generally called traumatic pulmonary pseudocyst (TPP). Traumatic pulmonary pseudocyst is usually seen in children and young adults, with 85% of patients being under the age of 30 years.<sup>1</sup> Management of TPP with supportive treatment generally yields good results and surgery is not needed.<sup>2</sup> However, surgery may be required if complications such as infections, bronchial bleeding or rupture into the pleural space occurs.

### 2. Case report

A fifty-two year old male patient was brought to our emergency department by ambulance after falling from a height of five meters. The patient's main complaints were chest pain and difficulty breathing. Upon physical examination, the patient was conscious, oriented, cooperative, and his Glasgow Coma Scale score was 15. The vital signs on admission were; body temperature 36.7 °C, pulse rate 80 per minute, blood pressure 130/90 mmHg, SaO<sub>2</sub> 94%,

respectively. His respiratory examination revealed that both lungs were participating in breathing equally, there was local tenderness to palpation in the right chest wall and rales were present in right pulmonary zones. In addition, tenderness to palpation was present in the cervical region, in the right thigh and right upper quadrant. In his chest radiograph (Fig. 1a) multiple rib fractures in the right hemithorax and a view consistent with diffuse contusion in the right lung was observed. In his pelvic radiograph fractures were observed in the right ramus superior and right ramus inferior. After two hours computed tomography (CT) scanning of the chest was performed for control of the lesions. There was consolidation and ground glass areas which were more significant in the posterobasal segment of the inferior lobe of the right lung. On the same level in the right costodiaphragmatic sinus, air cysts were present, the largest of which was 3.5 cm in diameter, possibly secondary to trauma (Fig. 1b). In addition, multiple slightly displaced fractures in the 1st, 2nd, 9th and 11th ribs were also detected in the CT. Complete blood count, liver enzymes, electrolytes, renal function test results of the patient were within normal limits. The patient was admitted to the emergency observation unit and consulted with thoracic surgery and pulmonology departments. The lesion described in tomography was considered to be TPP, primarily, because the patient had a history of trauma. We performed AFB smear testing of sputum because of the concern that the view in the CT imaging could be a sequel of tuberculosis. AFB smear testing yielded a negative result. Sputum culture was also negative for tuberculosis. The patient was discharged and followed as an outpatient. No further investigations for etiologic reasons other

\* Corresponding author.

E-mail address: [gulpamukcu@yahoo.com](mailto:gulpamukcu@yahoo.com) (G. Pamukcu Gunaydin).

Peer review under responsibility of The Emergency Medicine Association of Turkey.

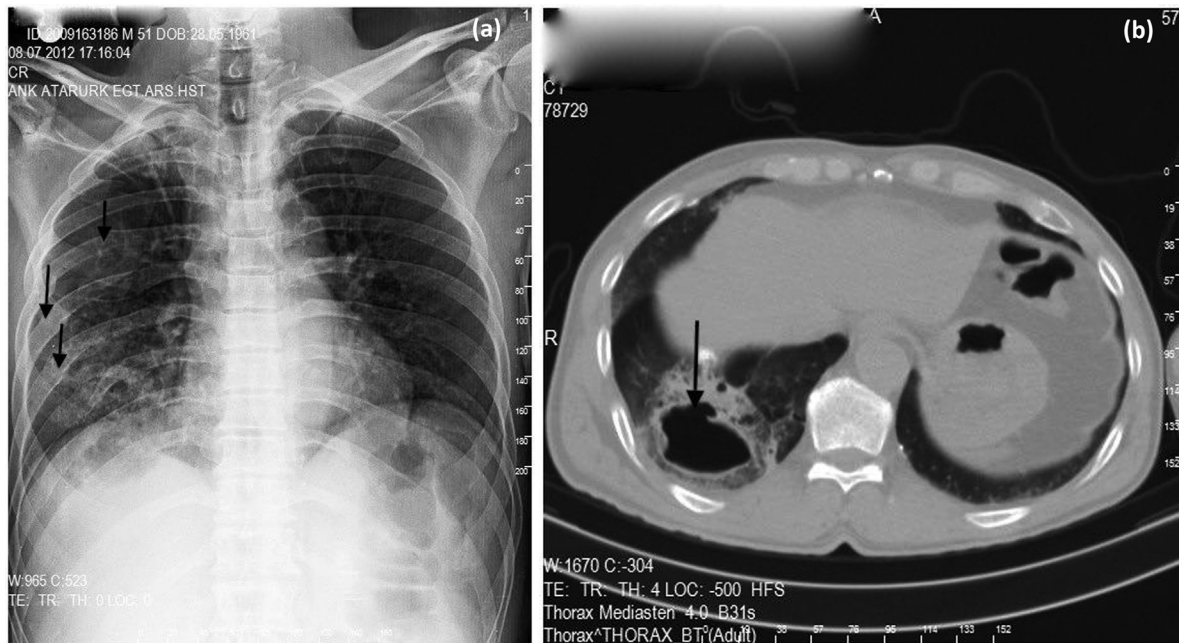


Fig. 1. (a) Chest x-ray. (b) Computed tomography of the chest.

than tuberculosis were needed since the lesion regressed in control radiological exams.

### 3. Discussion

Pulmonary contusion is one of the most common pathologies occurring after blunt thoracic trauma (% 30–75).<sup>3</sup> On the other hand TPPs are rarely occurring lesions after blunt chest trauma and comprise about 2.9% of all the parenchymal injuries due to blunt chest trauma.<sup>4</sup>

Several mechanisms are suggested for the development of TPP. The first mechanism is blowing up and tearing of the alveolar walls due to a sudden and high increase of pressure in the peripheral airways and expansion of trapped air. Another mechanism includes tears in the lung parenchyma caused by spreading waves.<sup>5</sup> The characteristic symptoms of TPP are dyspnea, hemoptysis, chest pain, cough, and fever.<sup>6</sup> In our case, the patient's main complaints were shortness of breath and chest pain.

TPPs are usually thin-walled and they can be completely filled with air or air-fluid levels can be seen. They are usually localized in the middle of pulmonary contusion or adjacent to it. In patients with chest trauma, a diagnosis of TPP is made by chest radiograph and computed tomography. Pseudocyst formation may not be viewed in the chest radiograph due to the presence of contusion and hematoma. However, these pseudocysts can be seen more clearly in the thorax CT. Therefore thorax CT is important for early diagnosis. CT is used in detection of the exact size and localization of the lesion, concomitant injuries and in the differential diagnosis of other diseases associated with cavitory lesions. TPP should be considered in the presence of single and sometimes multiple cavitory lesions in the shape of oval or round structures in the thorax CT imaging of the patients with blunt trauma. TPP may usually be seen a few hours and sometimes several days after the trauma.<sup>1</sup> In our patient, the chest radiograph revealed multiple rib fractures and extensive contusions on the right side of the lung, but no evidence of cysts were observed. Cystic lesions were detected in the CT imaging which we performed as a control two hours later.

TPP usually undergoes spontaneous resolution usually in 2–4 months.<sup>7,8</sup> For most patients with TPP, conservative medical treatment and follow-up is sufficient. Pseudocysts that grow progressively, get infected, form abscess or open into bronches do not completely resolve. These complicated cases may require surgery.<sup>7,9,10</sup> Moore et al.<sup>10</sup> reported that 38% of simple pneumocysts turn in to lung abscess. Gincherman et al. suggested that infected cysts can be treated successfully with CT-guided needle drainage.<sup>11</sup> In our case no complications were seen and he was discharged to be followed up as outpatient after medical treatment and observation for two days.

Soysal and colleagues<sup>1</sup> reported that two posttraumatic cystic lesions persisted in an 18-year-old patient and they resected the cavitory lesions surgically six months later. Çaylak et al.<sup>2</sup> reported two cases of posttraumatic cystic lesions which they followed conservatively and did not require surgical treatment. Yazkan, in his study of 73 cases of pulmonary contusions in isolated chest trauma reported that pseudocyst developed only in 4 of the patients in the area of contusion and spontaneous resolution was seen in all of those 4 patients (5.47%)<sup>12</sup> In our case, there was no complication after medical treatment as well.

Pulmonary abscess, bronchogenic cyst, lung cancer, blisters, blebs, cyst hydatid (in endemic areas), tuberculosis and coccidiomycosis may be considered in the differential diagnosis of TPP lesions. History of trauma and gradual decline of the lesion in the thoracic CT scan facilitates the diagnosis TPP.<sup>9</sup> In our case we performed additional assays due to the presumption that the lesion might be secondary to tuberculosis. The diagnosis of TPP has been clarified after the AFB smear and sputum culture is negative and clinical symptoms of the patient resolved during the follow up.

### 4. Result

TPP is a rare disorder seen due to chest trauma. In a systematic approach to the trauma TPP may be overlooked during the initial examination and may not be seen in the chest x-ray. For this reason, TPP should be considered in the differential diagnosis of patients

whose symptoms do not resolve. The diagnosis can be made by chest CT. Conservative management is sufficient in most cases.

### Conflicts of interest

The authors reported no conflict of interest.

### References

1. Soysal Ö, Kuzucu A, Kutlu R. Posttraumatic pulmonary pseudo cyst. *Turkish J Trauma Emerg Surg.* 1999;5:217–218.
2. Çaylak H, Kavaklı K, Sapmaz E, Yücel O, Genç O. Traumatic pulmonary pseudocyst: two case reports. *Turkish J Trauma Emerg Med.* 2011;17:269–272.
3. Boyd AD. Lung injuries. In: Hood RM, Boyd AD, Cullifort AT, eds. *Thoracic Trauma.* Philadelphia: WB Saunders Co; 1989:153.
4. Kocer B, Gulbahar G, Gunal N, Dural K, Sakinci U. Traumatic pulmonary pseudocysts: two case reports. *J Med Case Rep.* 2007;1:112.
5. De A, Peden CJ, Nolan J. Traumatic pulmonary pseudocysts. *Anaesthesia.* 2007;62:409–411.
6. Shirakusa T, Araki Y, Tsutsi M, et al. Traumatic lung pseudocyst. *Thorax.* 1987;42:516–519.
7. Kato R, Horunouchi H, Maeneka Y. Traumatic pulmonary pseudocyst. Report of twelve cases. *J Thorac Cardiovasc Surg.* 1989;97:309–312.
8. Wagner RB, Crawford Jr WO, Schimpf PP. Classification of parenchymal injuries of the lung. *Radiology.* 1988;167:77–82.
9. Ganske JG, Dennis DL, Vanderveer Jr JB. Traumatic lung cyst: case report and literature review. *J Trauma.* 1981;21:493–496.
10. Moore FA, Moore EE, Haenel JB, Waring BJ, Parsons PE. Posttraumatic pulmonary pseudocyst in the adult: pathophysiology, recognition and selective management. *J Trauma.* 1989;29:1380–1385.
11. Gincherman Y, Luketich JD, Kaiser LR. Successful nonoperative management of secondarily infected pulmonary pseudocyst: case report. *J Trauma.* 1995;38:960–963.
12. Yazkan R. Pulmonary contusion in adult isolated chest injuries: analysis of 73 cases. *Bidder Tıp Bilim Derg.* 2011;3:9–15.